

## Single rooted Posterior teeth: A rare root dysmorphism – three dimensional diagnosis

S. Jayachandran<sup>1</sup>, Bhaumik Joshi<sup>2,\*</sup>

<sup>1</sup>Professor & HOD, <sup>2</sup>PG Student, Dept. of Oral Medicine & Radiology, Tamilnadu Govt. Dental College, Affiliated to Tamilnadu Dr. MGR Medical University, Chennai

**\*Corresponding Author:**

Email: drbjoshi11@gmail.com

### Abstract

Developmental disturbances give rise to various forms of tooth dysmorphisms. It may lead to unusual size, shape, number or structure of tooth crown or roots. We endeavour to report an extremely rare form of Root Dysmorphism which presented with single root and single canal in all posterior teeth, along with a Dilacerated tooth and multiple impacted teeth. Confirmation was done using two dimensional (2D) and three dimensional (3D) reconstruction using Cone-Beam Computed Tomography (CBCT). This case is unique as generalized single rooted teeth with single canals along with Asyndromic multiple impacted teeth have not been reported previously.

**Keywords:** Anomalies, Tooth Root, Cone-Beam Computed Tomography, Computer-Assisted Three-Dimensional Imaging

### Introduction

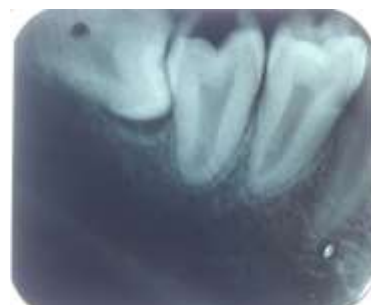Knowledge of anatomy of root and root canal is important determinant for various dental treatments including Endodontic, Orthodontic, Periodontal and other surgical treatments. Anatomical variations in the number of roots and root canals of multi-rooted teeth are widely documented in literature. Few examples include Supernumerary roots, Extra canals and decreased number of roots in isolated teeth.<sup>(1,2,3,4)</sup> Number of roots for the tooth is decided by invagination by Hertwig's epithelial root sheath (HERS) at epithelial diaphragm during root formation.<sup>(5)</sup> In this case we report presence of Single root and single canal in all premolars and molars along with a dilacerated tooth and multiple impacted teeth.

### Case Report

A 17 years old male patient presented with Complaint of a tooth erupting from upper labial vestibule and occasional pain in lower right back tooth region that was present for past 1 month. Intraoral examination revealed ectopically erupting Right Maxillary Canine; clinically missing left Maxillary Canine, Right and Left Maxillary 3<sup>rd</sup> molars and Right Mandibular 3<sup>rd</sup> Molar; Buccally Erupted Right and Left mandibular Second Premolars that failed to reach occlusion along with Carious Mandibular right 2<sup>nd</sup> molar and Mandibular left 1<sup>st</sup> molar. Patient's extraoral and general examination did not reveal any abnormal findings and he did not have any relevant past medical history.

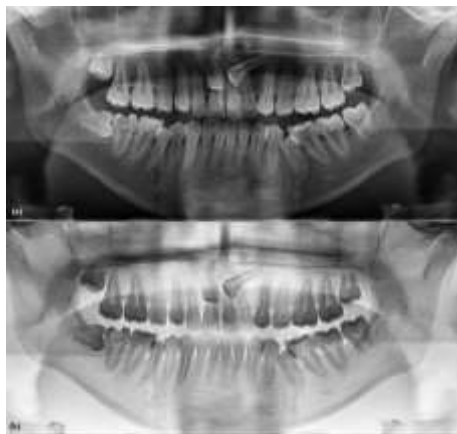Based on Clinical findings Intra oral Periapical (IOPA) radiograph of Mandibular right 2<sup>nd</sup> molar and an Orthopantomogram (OPG) were taken. IOPA revealed Carious Mandibular right 2<sup>nd</sup> molar and Horizontally Impacted Mandibular right 3<sup>rd</sup> molar. But amongst all, most striking feature was single root and

single root canal along with normal crown length and cervical constriction of canal at the level of CEJ in all the three teeth i.e. mandibular right 1<sup>st</sup>, 2<sup>nd</sup> and 3<sup>rd</sup> molars. (Fig. 1)



**Fig. 1: Intraoral Periapical Radiograph revealing single root and single canal of Mandibular right 1<sup>st</sup> 2<sup>nd</sup> and 3<sup>rd</sup> molar**

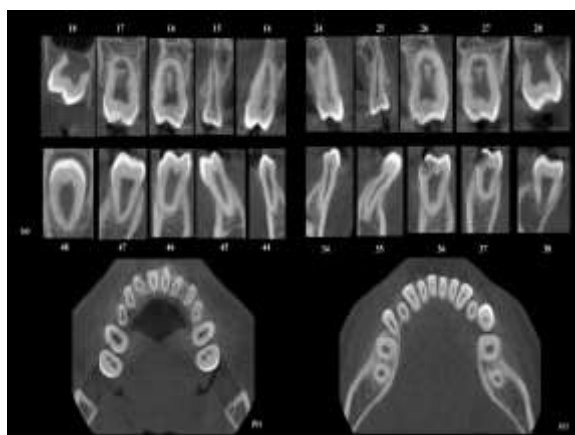
OPG revealed presence of single root with single canal in premolars and Molars of all four quadrants along with other findings i.e. Unerupted maxillary right and left 3<sup>rd</sup> molars with incomplete root formation, Impacted Mandibular right 3<sup>rd</sup> molar and maxillary right and left canines. Presence of single canals was enhanced with inverted OPG, which is negative view of radiograph obtained by inverting the brightness values of image pixels (Fig. 2)



**Fig. 2: Digital OPG (2a) and its inverted Image (2b) illustrate single rooted premolars and molars with single canals in all the four quadrants**

Following these Findings of IOPA and OPG, A CBCT scan was recorded to evaluate root anatomy and canal morphology. Reconstruction of axial, coronal, sagittal and panoramic slices at thickness of 180 microns at 85kv, 4mA with 8.01sec exposure and 10 X 10cm field of view confirmed single root and single canal in all the premolars and molars in two dimensional planes (Fig. 3a, 3b and 3c).

Additional details from CBCT included a dilacerated Mandibular left 2<sup>nd</sup> premolar and variations in the canal morphology in few teeth. All the teeth had vertucci's Class 1 pattern except Maxillary 1<sup>st</sup> and 2<sup>nd</sup> molars, Which exhibited Vertucci's Class 3 pattern.<sup>(6)</sup> (Fig. 3)



**Fig. 3: (a) Serial cross sectional CBCT images through Mesio-Distal centre of each tooth revealing presence of single root and single canal. An axial section through CEJ level in Maxillary (b) and Mandibular (c) arch shows single root and single canal in all the teeth including premolars and molars**

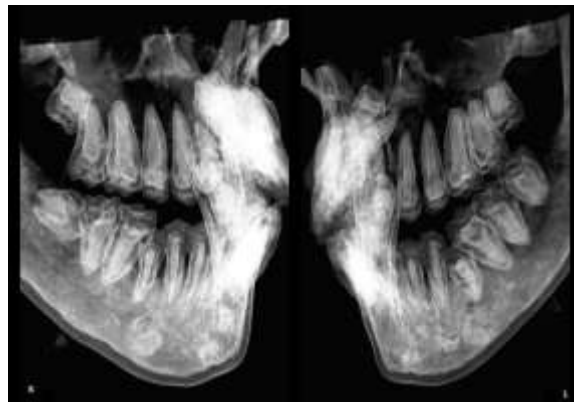
#### Legends:

18-28 Dentition From Maxillary Right 3<sup>rd</sup> molar to maxillary Left 3<sup>rd</sup> molar according to Fédération dentaire internationale (FDI) Nomenclature

38-48 Dentition from Mandibular Left 3<sup>rd</sup> molar to Mandibular Right 3<sup>rd</sup> molar according to FDI Nomenclature

CEJ- Cemento-Enamel Junction

3D reconstruction of Teeth along with root canals also revealed generalized single root canal morphology. (Fig. 4)



**Fig. 4: A Volumetric 3D Reconstruction image of CBCT of patient's Right(R) and Left (L) side clearly showing single roots with single root canals in Maxillary and Mandibular Premolars and Molars**

#### Discussion

Root Formation as well as its bifurcation and trifurcation follow structural changes in Hertwig's epithelial root sheath (HERS). HERS forms an Epithelial Diaphragm at the level of cervical loop once the crown formation ends. Invaginations from HERS Collar towards root centre decide number of root for a particular tooth.<sup>(5)</sup> Changes in HERS are controlled by epithelial signals i.e. Bone Morphogenic Protein (BMP), Fibroblast Growth Factor (FGF) sonic hedgehog gene (Shh) and wingless integration (Wnt) molecules.<sup>(7,8)</sup> These Signals affect morphogenesis of teeth by directing expression of various genes (MSX<sub>1</sub> and 2 for Incisors and HOMEBOX<sub>1,2,6,7</sub> for molars). Genetic alterations in any of these can lead to Dymorphogenesis of roots. In case of Failure by HERS to extend the projections from epithelial diaphragm will lead to formation of single rooted tooth.

A significant number of cases with isolated single rooted Permanent premolars and molars with single canal have been reported.<sup>(9,10)</sup> However reporting of generalised condition is very rare. Two cases were found in the literature with generalised single rooted permanent premolars and molars, but both of them had co-existing Asyndromic Hypodontia.<sup>(11,12)</sup> In contrast the presented case is unique in that patient had presence of all 32 teeth out of which 3 (Maxillary Right and Left canines and Mandibular right 3<sup>rd</sup> molar) were impacted

whereas 2 teeth (Mandibular right and left 3<sup>rd</sup> premolars) were out of occlusion and had partially erupted outside the arch. Considering Patient's age of 17 years, any comment regarding erupting condition of maxillary Right and left 3<sup>rd</sup> molar will be premature. A Significant amount of literature search concludes that a case of single rooted permanent premolars and molars with single canals, associated with Asyndromic multiple impacted teeth is being reported for the first time.

### **Conclusion**

We have presented a rare form of Root Dysmorphism associated with Asyndromic multiple impactions. CBCT imaging made precise evaluation of root and root canal morphology feasible by 2D Slicing as well as 3D Volumetric rendering of Image.

### **References**

1. Edgar Schäfer, Dominik Breuer, Sabine Janzen. The Prevalence of Three-rooted Mandibular Permanent First Molars in a German Population. *Journal of Endodontics* 2009 Feb; 35(2):202-205.
2. De Moor, R. J. G., Deroose, C. A. J. G. and Calberson, F. L. G. The radix entomolaris in mandibular first molars: an endodontic challenge. *International Endodontic Journal* 2004;37:789-799.
3. De Almeida-Gomes F, Maniglia-Ferreira C, Carvalho de Sousa B, Alves dos Santos R. Six root canals in maxillary first molar. *Oral Surg Oral Med Oral Pathol Oral Radiol Endod.* 2009 Sep;108(3):e157-9.
4. Roy, A., Velmurugan, N., & Suresh, N. Mandibular Second Molar with a Single Root and a Single Canal: Case Series. *Journal of Clinical and Diagnostic Research : JCDR* 2013;7(11):2637-2638.
5. Schroeder H. E. *Oral Structural Biology*. Stuttgart; New York, NY: Thieme Medical Publishers, 1991.
6. F. J. Vertucci, Root canal anatomy of the human permanent teeth, *Oral Surgery, Oral Medicine, Oral Pathology* 1984;58(5):589-599.
7. Tucker A, Sharpe P. The cutting-edge of mammalian development; how the embryo makes teeth. *Nat Rev Genet* 2004;5(7):499-508.
8. Jernvall J, Thesleff I. Reiterative signaling and patterning during mammalian tooth morphogenesis. *Mech Dev* 2000;92:19-29.
9. Shigli A, Agrawal A. Permanent maxillary first molar with single root and single canal: A case report of a rare morphology. *J Indian Soc Pedod Prev Dent* 2010;28:121-5.
10. Chandrasekaran Sooriaprakas, Suma Ballal, and Natanasabapathy Velmurugan, "Mandibular First Molar with a Single Root and Single Canal," *Case Reports in Dentistry*, vol. 2014, Article ID 159846, 4 pages, 2014.
11. Jeddy N, Radhika T, Nithya S, Krithika C, Prabakar R. Single Rooted Permanent Premolars and Molars - A Rare Clinical Presentation Confirmed using Cone Beam Computed Tomography. *Journal of Clinical and Diagnostic Research: JCDR.* 2015;9(8):ZD15-ZD17.
12. Agarwal, A., Gundappa, M., Miglani, S., & Nagar, R. Asyndromic hypodontia associated with tooth morphology alteration: A rare case report. *Journal of Conservative Dentistry: JCD* 2013; 16(3):269-271.