

## Prevalence, gender distribution and pattern of zygomatic air cell defects in Chhattisgarh population –an orthopantomographic study and review with importance

R.S. Sathawane<sup>1</sup>, Deepti Patel<sup>2,\*</sup>, Y. Bharani Devi<sup>3</sup>, Nikita Agrawal<sup>4</sup>

<sup>1</sup>Professor & HOD, <sup>2,4</sup>PG Student, <sup>3</sup>Senior Lecturer, Dept. of Oral Medicine & Radiology, Chhattisgarh Dental College & Research Institute, Rajnandgaon, Chhattisgarh

**\*Corresponding Author:**

Email: writetonikitaagrawal@gmail.com

### Abstract

**Introduction:** Pneumatized air cells, an accessory air cells similar to the mastoid air cells, seen in the zygomatic process and articular eminence of temporal bone are termed as Zygomatic Air Cell Defects (ZACDs). Several authors have suggested the importance of these air cell as contraindication and possible complicating factor for performing surgical procedures such as eminoplasty or eminectomy as they can become potential pathways for intracranial infections and sepsis. It was also strongly emphasized that an awareness of ZACDs should be a part of our anatomical knowledge.

**Aim and Objectives:** To study the prevalence, gender distribution, pattern of occurrence, and radiographic appearance of ZACDs on orthopantomographs in Chhattisgarh population, and to make aware the diagnosticians and surgeons about ZACDs so as to prevent potential post-surgical complications.

**Materials and Method:** Orthopantomographs of 240 subjects were evaluated genderwise & radiographic pattern-wise retrospectively for ZACDs. Chi square test was used for statistical analysis.

**Result:** Out of 240 Orthopantomographs, ZACDs were seen in 16 subjects with male to female ratio of 2.2:1 and overall prevalence of 6.67%.

**Conclusion:** Though the overall prevalence of ZACDs is less, the diagnostician & surgeons should carefully evaluate radiographs for ZACDs before dealing with zygomatic process & articular eminence; and this pneumatization should be taught as a part of anatomical knowledge.

**Keywords:** Orthopantomographs, Pneumatisation, Zygomatic Process, Mastoid Process, Articular Eminence, Zygomatic Air Cell Defects.

### Introduction

Zygomatic air cell defects (ZACDs) are defined as pneumatised/ accessory air cells in the zygomatic process and articular eminence of temporal bone which do not extend beyond zygomaticotemporal suture.<sup>(1)</sup> Identification of ZACDs is more important from surgical perspective than epidermological view as surgical procedures can result in inadvertent penetration through the defects producing communication with infratemporal / middle cranial fossa, dural tear, hemorrhage, CSF leakage and infection.<sup>(2)</sup> Lindemuth and Clark emphasized that awareness of pneumatization should form a part of anatomical knowledge.<sup>(3,4)</sup> Therefore, the present study has been carried out to find the prevalence & pattern of ZACDs in Chhattisgarh population.

### Materials and Method

This is a retrospective study done on digital panoramic radiographs, taken on Sirona Orthophos X45 digital panoramic x-ray machine (having 60-90 kVp, 3-16 mA, 5-22 sec exposure time parameters), of subjects with the age range of 20-62 years who visited department of OMR, Chhattisgarh Dental College & Research Institute, Rajnandgaon (C.G.). The sample comprised of 240 panoramic radiographs of the subjects divided into 3 groups according to age in either gender

each comprising 40 radiographs. Group I consisted of radiographs of subjects in the age range of 20-29 years, group II in the age range of 30-39 years, and group III in the age range of 40-62 years.

Radiographs of the subjects with developmental malformations of the face and jaws, systemic conditions affecting growth, clinical or radiographic evidence of pathologies in the maxillofacial region, and those with a history of trauma to the maxillofacial region and treated with surgical intervention were excluded from the study. Panoramic radiographs were examined thoroughly & evaluated for the presence and pattern of ZACDs. The finding were recorded and grouped as unilateral or bilateral, and unilocular or multilocular types. The data was tabulated and subjected to statistical analysis. Chi square test was performed.

### Results

Out of 240 study subjects, ZACDs were seen in 16 subjects (Table 1) giving an overall prevalence of 6.67%. Out of 16 subjects with ZACDs, 6 were in Group I, 4 in Group II and 6 in Group III. Out of 16 subjects with ZACDs, 11 were males and 5 were females, the male to female ratio being 2.2:1.

Table 1 depicts gender wise distribution of ZACDs according to location. In Group I, out of 6 subjects with ZACDs, 4 were males and 2 were females; in males, 3

were having unilateral and 1 was having bilateral ZACDs, whereas in females, both were having unilateral ZACDs. In Group II, out of 4 subjects with ZACDs, 2 were males and 2 were females and all were having unilateral ZACDs. In Group III, out of 6 subjects with ZACDs, 5 were males and 1 was female and all had unilateral ZACDs. The Chi square test was performed and on comparison between the groups the p values were found to be 0.047 for males and 0.018 for females which were significant.

Table 2 depicts gender-wise distribution of ZACDs according to pattern. In Group I, all 6 subjects of

ZACDs (4 males & 2 females) showed multilocular pattern. In Group II, out of 4 (2males & 2 females) subjects of ZACDs, both males showed multilocular pattern, whereas both females showed unilocular pattern. In Group III, out of 6 subjects of ZACDs (5 males & 1 female), 4 males had unilocular and 1male had multilocular pattern, whereas 1 female showed multilocular pattern. The Chi square test was performed and on comparison between the groups the p values were found to be 0.33 and 0.403 for males and females respectively which were non-significant.

**Table 1: Gender wise Distribution of ZACDs According to Location**

Gender	Age group	Total subjects	Unilateral		Bilateral		P value
			n=	%	n=	%	
Male	Group-I 20-29 years	40	3	7.5	1	2.5	0.047*
	Group-II 30-39years	40	2	5	0	0	
	Group-III 40-62 years	40	5	12.5	0	0	
	<b>Total</b>	120	10	8.3	1	0.8	
Female	Group-I 20-29 years	40	2	5	0	0	0.018*
	Group-II 30-39years	40	2	5	0	0	
	Group-III 40-62years	40	1	2.5	0	0	
	<b>Total</b>	120	5	4.1	0	0	

\*Chi square test: P Value – Significant

**Table 2: Gender wise Distribution of ZACDs According to Pattern**

Gender	Age group	Total subjects	Unilocular		Multilocular		P value
			n=	%	n=	%	
Male	Group-I 20-29 years	40	0	0	4	10	0.33*
	Group-II 30-39 years	40	0	0	2	5	
	Group-III 40-62 years	40	4	10	1	2.5	
	<b>Total</b>	120	4	3.3	7	5.8	
Female	Group-I 20-29 years	40	0	0	2	5	0.403*
	Group-II 30-39 years	40	2	5	0	0	
	Group-III 40-62 years	40	0	0	1	2.5	
	<b>Total</b>	120	2	1.6	3	2.5	

\* Chi square test: P Value – Non Significant

**Table 3: Showing prevalence rates, gender distribution, occurrence(unilateral/bilateral) and imaging modalities used in different studies on ZACDs<sup>(8)</sup>**

Researchers & Years	Sample size	Prevalence	Male	Female	Unilateral cases	Bilateral cases	Imaging modality
Tyndall & Matterson 1985	1061	28(2.6%)	13	15	23	5	Panoramic radiography
Kaugars et al 1986	784	8(1%)	1	7	4	4	Panoramic radiography
Carter et al 1999	2734	40(1.5%)	20	20	32	8	Panoramic radiography
Hofmman et al 2001	1084	20(1.8%)	9	11	16	4	Panoramic radiography
Orhan et al 2005	1006	19(1.9%)	7	12	12	7	Panoramic radiography
Orhan et al 2006	1049	17.(1.62)	9	8	10	7	Panoramic radiography
Yavus et al 2009	8107	83(1.0.3%)	42	41	56	27	Panoramic radiography
Orhan et al 2010	1405	48(3.42%)	12	36	32	16	Panoramic radiography
Miloglu et al 2011	514	41(8%)	16	25	31	10	Cone beam CT
Zamaninaser A et al 2012	2600	94	35	59	70	24	Panoramic radiography
Shokri et al 2013	1563	98(6.2%)	33	65	64	34	Panoramic radiography
Srivathsa et al 2014	1688	50(2.96%)	23	27	38	12	Panoramic radiography
Arora et al 2014	600	19(3.16%)	6	13	9	10	Panoramic radiography
Khojastepour et al	3098	64(2.1%)	23	41	40	24	Panoramic radiography
Riberio-Nascimento et al 2015	698	23(3.3%)	13	10	7	16	Cone beam CT
Mosavat et al 2015	239	51 (21.3%)	25	26	35	16	Cone beam CT
Liguy et al 2015	111	73(65.8%)	19	54	31	42	Cone beam CT
Arora et al 2016	6825	133(1.94%)	84	49	112	21	Panoramic radiography

## Discussion

Pneumatization refers to the presence or development of air-filled cavities in a bone. In addition to major paranasal sinuses, accessory air cells may arise in numerous locations in the skull, including the temporal bone, either singly or in clusters. Tyndall and Matteson (1987) coined the term 'zygomatic air cell defects'(ZACDs) to describe accessory air cells occurring in the root of the zygomatic arch and articular eminence of the temporal bone. The term pneumatized articular tubercle(PAT)/ eminence was coined by the same researches in 1985. Its cause is unknown, but it

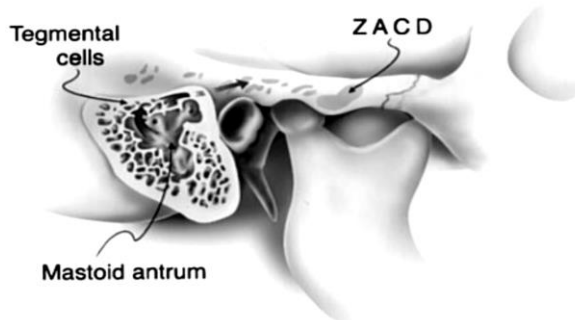
seems to be similar to that of pneumatization of mastoid process.<sup>(5,6,7)</sup>

**Mechanism of Pneumatization:** Pneumatization starts with the formation of small osseous cavities created by normal periosteal activity. The primitive bone marrow present in these cavities differentiates into a loose mesenchymal connective tissue, later invaginated by epithelium producing a mucous membrane which then undergoes atrophy, leaving a thin residual lining membrane attached to the periosteum. Continued subepithelial bone resorption further expands the air cells that vary in size and shape, become more distinct

with time because of progressive calcification of their walls. Reception of sound, resonance of voice, protection from external violence, lightening the weight of the skull, insulation, acoustic dissipation and the air reservoir functions etc. are thought to be attributed to these cells. The function of air reservoir of the middle ear states that when the function of the eustachian tube decreases, the air in the temporal bone acts to prevent developing negative pressure due to absorption of air by the middle ear mucosa, thereby, preventing changes of the middle ear mucosa as well as progression of otitis media.<sup>(1,4,5,8,9)</sup>

**Stages of Pneumatization:** Pneumatization of the temporal bone is divided into three stages: infantile (birth to 2 years), transitional (2- 5 years) and adult stage. In the infantile stage, air cells begin to appear in the mastoid antrum. In the transitional stage, the squamomastoid undergoes gradual enlargement with migration of air cells towards the periphery. The air cells become more distinct radiographically after puberty, owing to progressive enlargement and calcification of their walls (Fig. 1).<sup>(5)</sup> Pneumatization ceases during the adult stage, generally at the close of puberty.<sup>(2)</sup> The characteristics of the pneumatized articular tubercle (PAT) of the temporal bone were identified and described as:-

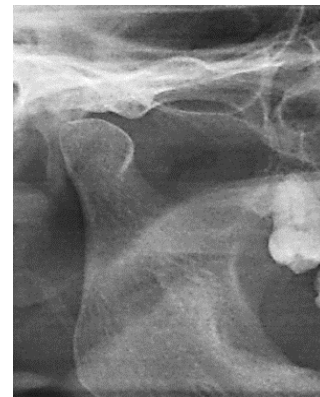1. Asymmetric radiolucent defect in the zygomatic process of the temporal bone with appearance similar to mastoid air cells.
2. Extension of defect anteriorly as far as the articular tubercle but not beyond the zygomaticotemporal suture, and
3. No enlargement or cortical destruction of the zygoma.<sup>(5,6)</sup>



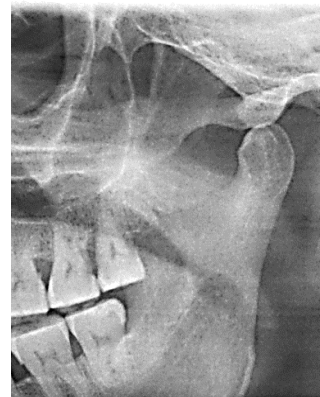**Fig. 1: Sagittal section of right squamomastoid region showing the peripheral extension of air cells from the mastoid antrum to the zygomatic process and articular eminence. (courtesy- LC Carter et al.)**

**Classification:** Tyndall and Matteson in 1985 classified ZACDs into three types as Unilocular (Fig. 2), Multilocular (Fig. 3), and Trabecular type. ZACDs are asymptomatic, non-expansile & non-destructive radiolucencies. Unilocular variant presents as an oval radiolucent defect with well defined borders, and the multilocular one demonstrates numerous small cavities

within, resembling mastoid air cells. The trabecular type is basically a multilocular entity with internal bony striations.<sup>(1,2,4)</sup>



**Fig. 2: OPG showing unilocular ZACDs on right side**



**Fig. 3: OPG showing multilocular ZACDs on right side**

**Imaging Modalities:** Panoramic imaging is the most useful method for diagnosing PAT. Trans-orbital view can also be an adjunctive projections for visualization of PAT. However, radiographic projections like submentovertex, transcranial, Towne's, or Water's views do not provide good visualization of the articular eminence.<sup>(5)</sup>

**Prevalence:** Various studies have been conducted for ZACDs using different imaging modalities over the years. A wide variation of prevalence rates of ZACDs have been observed ranging from as low as 1% to as high as 65.8% (Table 3).<sup>(10,11)</sup> However, most of the researchers who evaluated the ZACDs using the panoramic radiographs have found prevalence rates lower than 5%. Only one study conducted by Shokri et al in 2013 using panoramic radiography reported a prevalence rate of 6.2%. In contrast, most of the studies using the CBCT have reported higher prevalence rates, as high as 68.5%. However, only one study has reported lower prevalence rate of 3.3%.<sup>(10)</sup>

**Differential Diagnosis:** The ZACDs occur in the zygomatic arch with any frequency and present as an

asymptomatic, non-expansile, non-destructive radiolucency detected incidentally on a radiograph. Its differential diagnosis include aneurysmal bone cyst, hemangioma, giant cell tumor, eosinophilic granuloma, fibrous dysplasia, and metastatic tumor. These entities are usually characterized by painful cheek enlarging masses, facial asymmetry, bony expansion with cortical destruction and frequently mixed density lesions with fine internal radiopaque flecks or striae. The review of literature revealed only two cases of aneurysmal bone cyst in the body of the zygoma, presenting with pain and swelling in the cheek, functional impairment and with expansile radiolucent lesions, both in teenage males.<sup>(5,11)</sup>

Osseous hemangioma is rare, with an incidence of only 0.5 -1.0% of all neoplasms of bone. Usually it shows a predilection for the vertebral column, calvarium and long bones. Although it is known to occur in the maxilla and mandible, osseous hemangioma involving the zygoma is extremely rare, with only 22 cases appearing in the literature since 1966.<sup>(5)</sup> Most of these have presented as hard infra-orbital masses; none have been reported in the zygomatic arch. Clinically, hemangiomas of the zygoma present as a gradually but continuously enlarging swelling which is often characterized by local tenderness and upward displacement of the globe. Radiographs reveal a uni- or multi- locular, often honeycomb, expansile radiolucency which frequently contains multiple striations or a sunburst appearance.<sup>(1,5)</sup>

Fibrous dysplasia may affect the cranial bones, especially the frontal and sphenoid bones, followed by the ethmoid and parietal bones and very rarely temporal and occipital bones. There is only one reported case of involvement of the zygomatic arch by fibrous dysplasia.<sup>(5)</sup> It is noteworthy to remember that if the temporal bone is involved, all portions of the bone are usually affected. The most common presenting symptoms of fibrous dysplasia affecting the temporal bone, in order of decreasing frequency, are progressive loss of hearing, gradual swelling and change in contour of the temporal bone, and progressive bony obliteration of the external auditory canal. Radiographic features vary with the level of maturation of the disease process such that early lesions will appear radiolucent but mineralization of matrix will produce an increase in bone density, frequently with a ground glass, orange peel or fingerprint pattern.<sup>(1,5)</sup>

Involvement of the temporal bone by eosinophilic granuloma is extremely rare, with 30 cases having been reported in the literature, none of these was involving the zygomatic arch. Eosinophilic granuloma of the temporal bone erodes the mastoid cortex, destroys the tegmen, and then erodes the semi-circular canals or cochlea. The lesion typically presents as an aural polyp or a postauricular swelling with chronic otorrhea. Radiographic features include a well-demarcated, expansile, destructive radiolucency which arises in the

diploic space and preferentially affects the outer skull table, resulting in the characteristic beveled edge appearance.<sup>(5)</sup>

**Treatment:** Since the ZACDs are pneumatized accessory air cells, they require no treatment but their identification is very important from the surgical perspective than that of epidermiological view.<sup>(5)</sup>

### Conclusion

The overall prevalence of ZACDs in Chhattisgarh population was found to be 6.67% with the peak age of the defect being 20-29 years and male to female ratio of 2.2:1.

The present study too observed the similar characteristics pattern of ZACDs as described earlier by Tyndall and Matteson. No other variations were found. When ZACDs are evident on the preoperative radiograph, eminoplasty or eminectomy is contraindicated. Therefore, there is a need for thorough preoperative imaging evaluation. Though ZACDs require no treatment, the Diagnosticians & Maxillofacial Surgeons should be aware of such occurrence of variations of the zygomatic process and articular eminence, so as to prevent unexpected complications during surgical interventions.

**Conflict of interest:** None

**Financial support:** Nil

### References

1. Srikanth H. Srivathsa, Mahima V. Guledgud, Karthikeya Patil: Zygomatic air cell defect, Journal of Cranio-Maxillary Diseases 2012;1(2):95-104.
2. Ashish Zamaninaser, Roghayeh Rashidipoor, Farzaneh M osavat and Ahura Ahmadi: Prevalence of Zygomatic Air Cell Defects: Panoramic Radiographic study of a selected esfahanian population. Dent Res J. 2012;9:S63-S68.
3. Ankita Bohra, Basavraj T Bhagwati, Neelkant Patil, Anitha B, Sumit Bhatija: Prevalence of Zygomatic air cell defect: A panoramic radiographic study, Indian J Dent Adv 2015;7(2):97-100.
4. Bhargavi Dasari, Ravi Kiran, Samatha Y, Udaya Sindu Y, Kartheeki B, Hima Bindu M, Purna Chandra Rao Nayak : Prevalence of Zygomatic Air Cell Defects in a South Indian Population- A retrospective study, Dentistry, an open access journal 2016;6(8):1000390.
5. LC Carter, AD Haller, AD Calamel and AC Pfaffenbach: Zygomatic air cell defect (ZACD).Prevalence and characteristics in a dental clinic outpatient population, Dentomaxillofacial Radiology 1999;(28):116-122.
6. Karandeep Singh Arora, Nagesh Binjoo, Lalit Singh Negi, Richa Modgil, Mohit Sareen, Prabhpreet Kaur, Shreyam Mohapatra: Zygomatic Air Cell Defect: A Panoramic.
7. Radiographic Study of Population Of Jaipur And Surrounding Areas J Oral Maxillofac Pathol Med |Jan-Jun 2014;1(1):28-30.
8. Malikaa Kishore, Sunil R. Panat, Abhinav Kishore, Ashish Aggarwal, Nitin Upadhyay, Nupu Agarwal: Prevalence of Zygomatic Air Cell Defect using Orthopantomogram, J Clin Diagn, Res.2015 Sep;9(9):ZC09-ZC11.

9. Rohit Gadda, Neha Anil Patil, Rohini Salvi: Zygomatic Air Cell Defect: Prevalence and characteristics in dental outpatient population, *Journal of contemporary dentistry*, September- December 2012;2(3):69-72.
10. Leila Khojastepour, Sanam M Irbeigi, Noshafarin Zeghami: Pneumatized articular eminence and assessment of its prevalence and feature on panoramic radiographs. *Journal of dentistry, Tehran university of medical sciences*.2015;12(4):235-242.
11. Shishir Ram Shetty, Sura Ali Ahmed Foud Al-Bayati, Shakeel Santerbennur Khazi, Sessa Manchala Reddy: Zygomatic Air Cell Defect – a Brief Review. *AMAJ* 2016;3:89-92.
12. Abbas Shokri, Maruf Noruzi-Gangachin1, Maryam Baharvand, Hamed Mortazavi: Prevalence and characteristics of pneumatized articular tubercle: First large series in Iranian people, *Imaging Science in Dentistry* 2013;43:283-7.