

## Determination of gender from occlusal radiographic measurements

R.S. Sathawane<sup>1</sup>, Kanak Tripathi<sup>2,\*</sup>

<sup>1</sup>Professor & HOD, <sup>2</sup>PG Student, Dept. of Oral Medicine & Radiology, Chhattisgarh Dental College & Research Institute, Rajnandgaon, Chhattisgarh

**\*Corresponding Author:**

Email: kanak.tripathi.11@gmail.com

### Abstract

**Introduction:** Gender determination not only reflects a social demand, but also follows medico-legal requirements. Many-a-times, only the part of skull is available for forensic examination. Cases where corpses are unrecognizable, medical/dental records and radiographs help in differentiation of gender. Dental arches analysis by occlusal radiographic measurements can be used for identification of a person.

**Aim:** To determine gender by analyzing dental arches using occlusal radiographic measurements.

**Materials and Method:** One hundred twenty standard occlusal radiographs of 30 males and 30 females in age range of 20-25 years were taken and traced. Median line and a line touching vestibular portions of central incisors were drawn. From this intersecting point 'I', a line was drawn to vestibular portion of canine, second premolar and second molar on both sides, in both arches, for angular measurements. Linear measurements relative to the width of the arches were made in three segments- canines, premolars and second molars. The obtained data was statistically analysed.

**Result:** All the linear measurements were larger in males than in females. All linear measurements were found statistically highly significant, suggesting very good gender differentiation; whereas only two angles 'MIC'L and 'CIA'L were found applicable ( $p < 0.05$ ) for gender differentiation.

**Conclusion:** Linear measurements can be used as a definite key measurements for gender differentiation in Indian population, whereas only two angular measurement can be used for gender determination.

**Keywords:** Forensic examination, Gender determination, Dental arches analysis, Occlusal radiographic measurements.

### Introduction

Gender identification is one of the major and most important task of Forensic Medicine and Dentistry. The identification of a deceased individual holds social and legal repercussions.<sup>(1,2)</sup> Determination of gender is the keystone to establish a biological profile from skeletal remains as it reduces possible matches by 50%.<sup>(3)</sup> Non-mutilated remains do not pose much difficulty in identification, but the challenge lies in identifying mutilated body parts when only a part of skeleton or bone is found.<sup>(4)</sup> Skull is the second most commonly sexed bone for determination of gender.<sup>(5)</sup> Mandible is also the commonly found intact bone. Because of its compact nature, it can be used in gender identification as it expresses strong univariate sexual dimorphism.<sup>(6)</sup> Thus, dental arches analysis can be used to determine gender.<sup>(7)</sup>

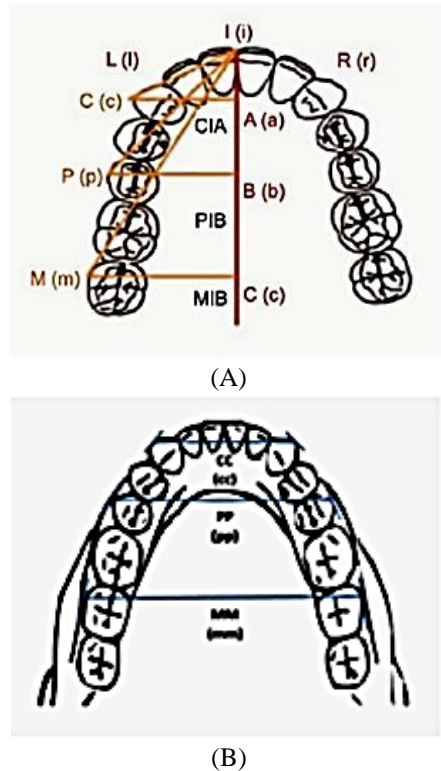
Search of literature revealed no published studies on gender determination by linear and angular measurements of dental arches by occlusal radiographs in Indian population. Therefore, the present study was designed and carried out with the aim of analyzing dental arches for gender determination by using occlusal radiographic linear and angular measurements.

### Materials and Method

The study was approved by Institutional Ethics Committee of Chhattisgarh Dental College & Research Institute, Rajnandgaon, Chhattisgarh, India. The study subjects included 30 males and 30 females in the age

range of 20-25 years, selected from a population of students by simple random sampling method. Subjects having normally erupted and aligned complete dentition (class I dentition) and 'U' shaped palate were included in the study. Subjects with periodontal diseases, morphological tooth abnormalities like attrition, caries etc., H/o tooth extractions/ missing tooth (except third molars), any abnormalities in maxillary and mandibular dental arches anatomy, gross facial asymmetry, developmental disorders of jaws, skull & facial pathologies and craniofacial trauma, H/o surgical orthodontic treatment, and history and clinical features suggestive of endocrinal, hereditary and nutritional disturbances were excluded from the study. After their written consent, standard occlusal radiographs (60 maxillary and 60 mandibular) were taken on Technomac dental X-ray machine with 70kVp, 8 mA and 1.2 sec exposure parameters after taking due radiation protection and safety measures.

The radiographs were traced and the measurements were done as shown in Fig. 1(A), (B), attributing Capital letters to the maxillary arch and small letters to the mandibular arch. Letter L and l, and R and r denote left side and right side of the maxillary and mandibular arches respectively.



**Fig. 1: Schematic illustration of Angular (A) & Linear (B) Measurements (Courtesy: Leticia Ferreira et al)**

Median line and a line touching the vestibular portions of the projections of the maxillary central incisors were drawn. The intersection of these points was called as point “I”. From this point, another line was drawn towards the most vestibular portion of the canine tooth (“C” point), and this line named as linear

measure “IC”. The angle formed by these two points and “A” point, locating in the line that coincides with the union of the palatal processes of maxillary bone, i.e. medial line, named as CIA”. Following the same methodology, a line from “I” point to the most vestibular portion of the second pre-molar (“P” point) and second molar (“M” point) were drawn and named as linear measure “IP” and “IM” respectively. The angle obtained by these two points (“IP” & “IM”) and “B” & “C” points located in the line that coincides with the medial line of palate, called as “PIB” & “MIC” respectively. Similarly in mandibular arch the angular measures abbreviated as “cia”, “pib”, “mic” and linear measures as “ic”, “ip” and “im”. Measures related to the maxillary and mandibular dental arches width were made in three portions corresponding to line drawn from the most vestibular portions of left and right canines, second premolars and second molars.

Data was analyzed using SPSS Software Version 22.0. The values were compared between the sexes using student t-test (p<0.05) with 95% C.I. for gender influences over the variables/parameters.

**Results**

Mean and standard deviation linear measurements and angular measurements obtained for males and females are presented in Table 1 & 2 respectively. All the linear variables showed higher values in males than in females which were found statistically highly significant for gender differentiation. Angular measurement values have shown highly significant differences (p<0.004) between males and females in “CIA L” and “MIC L” angle measures only.

**Table 1: Showing Linear Measurements (cm)**

		CC	PP	MM	cc	pp	mm
Male	Mean	3.91	5.26	6.32	3.08	4.7	6.126
	±SD	0.32	0.194	0.144	0.09	0.21	0.177
Female	Mean	3.7	5.09	6.006	3.03	4.49	6.04
	±SD	0.27	0.252	0.157	0.046	0.2	0.096
Results	t-test	2.582	2.928	8.073	2.71	3.966	2.339
	p-value	0.013	0.005	<0.001	0.009	<0.001	0.023
		HS	HS	HS	HS	HS	MS

**Table 2: Showing Angular Measurements**

		CIAL	PIBL	MICL	CIAR	PIBR	MICR	cial	piibl	micl	ciar	pibr	micr
Male	Mean	68.5	50	38.5	66.83	48.5	37	70	51.5	37.5	69.5	51.33	37
	±SD	2.33	3.47	2.33	2.78	3.97	2.49	0	2.33	2.54	1.52	2.24	2.49
Female	Mean	66.66	48.5	36.66	66.66	48.5	37	70	51	37.16	69.5	50.16	36
	±SD	2.39	2.33	2.39	2.39	2.33	2.49	0	2.03	2.52	1.52	2.78	2.03
Results	t-test	3.019	1.966	3.019	0.254	0	0	0	0.886	0.52	0	1.795	1.705
	p-value	0.004	0.054	0.004	0.8	1	1	1	0.38	0.61	1	0.077	0.094
		HS	NS	HS	NS	NS	NS	NS	NS	NS	NS	NS	NS

## Discussion

Determination of gender plays an imperative role in establishing the biological profile of the deceased.<sup>(5,8)</sup> The main attributes of biological identity are age, sex, stature and ethnicity- the “Big Fours” in forensic context.<sup>(4)</sup> When a part of the bone of mutilated body is found, it poses a challenge in identification. Skull is possessed of hard structures, due to which it is the foremost maintained part of skeleton. In addition to skull, mandible is also the commonly available intact bone.<sup>(9)</sup> In recent times, gender dimorphism have been studied with various metric parameters and are found advantageous and reliable in distinguishing gender dimorphism among different populations.<sup>(10)</sup>

There are few researches relating to size and shape of dental arches. Merz<sup>(11)</sup> observed that there was no significant differences between genders and concluded that synergic study of tooth size and arch shape might contribute to gender dimorphism. Therefore, the present study was undertaken to determine sex from the linear and angular measurements obtained from standard occlusal radiographs.

In the present study, all the linear measurements are found highly significant in gender differentiation. Only two angular measurements namely “CIA L” and “MIC L” are found highly significant in differentiation of sex. The results of the present study are in accordance with the results of the study done by Leticia et al<sup>(13)</sup> in Brazilian population.

Relationship between arch size vary among gender indicating bigger sizes in males. Dentofacial relationship, the tissue that involves them, occlusion, dental arches variability and genetic component are related to the differences found in the maxilla and mandible, whereas coronal morphology and permanent teeth sizes are unchanged during growth and development process, except for nutritional abnormality or disorders inherited in other pathological conditions.<sup>14</sup> Thus, occlusal radiographic measurements (odontometry) can be used for gender determination. The main advantages of this method are: it is simple, quick and accurate technique for gender determination by using all linear measurements, and “CIA L” and “MIC L” angular measurements.

## Conclusion

Comparison between sexes showed that linear measurements were higher in males than in females. All the occlusal radiographic linear measurements showed statistically highly significant sex differences. Thus, all the linear measurements can be used individually as definitive key in gender differentiation.

Only “CIA L” and “MIC L” angular measurements showed statistically highly significant gender differentiation between the males and the females. Therefore, only these two angular measurements can be used as definitive key in gender differentiation.

Individual dental arch i.e. either maxillary or mandibular dental arch can be used in gender differentiation.

**Conflict of Interest:** None

**Funding:** None

## References

1. Borges SR. Sexual dimorphic characteristics. Qualitative variations in facial areas and distances, by means of lateral cephalometric radiographs in white adult. *Rev Bras Odontol.* 1977;31:118-27.
2. Patil KR, Mody RN. Determination of sex by discriminant function analysis and stature by regression analysis- a lateral cephalometric study. *J Forensic Sci. Int.* 2005;147(2-3):175-180.
3. Scheur L. Application of osteology to forensic medicine. *Clin. Anat.* 2002;15(4):297-312.
4. Rogers TL. Determination of sex of human remains through cranial morphology. *J Forensic Sci.* 2005;50(3):493-500.
5. Naikmasur VG, Shrivastava R, Mutalik S. Determination of sex in South Indians and Immigrant Tibetans from cephalometric analysis and discriminant functions. 2010; 197(1-3):122.e1-6.
6. Shamim T. Forensic Odontology. *J Coll Physicians Surg Pak.* 2010;20(1):1-2.
7. Gupta A, Kumar K, Shetty DC, Wadhwan V, Jain A, Khanna KS. Stature and gender determination and their correlation using odontometry and skull anthropometry. *J Forensic Dent Sci.* 2014;6:101-6.
8. Mathur UR, Mahajan AM, Dandekar RC, Patil RB. Determination sex using discriminant function analysis in young adults of Nashik: A Lateral Cephalometric Study. *J Adv Dent Sci.* 2014; 2(1):21-25.
9. Indira AP, Markande A, David MP. Mandibular ramus: An indicator for sex determination - A digital radiographic study. *J Forensic Dent Sci.* 2012;4:58-62.
10. Camps FE. Gradwohl's legal medicine. 3<sup>rd</sup> ed. Wright and Son: Bristol John;1976.
11. Merz ML. Tooth diameters and arch perimeters in a black and white population. *Am J Orthod Dentofac Orthop.* 1991;100:53-8.
12. Altherr ER, Koroluk LD, Phillips C. Influence of sex and ethnic tooth-size differences on mixed-dentition space analysis. *Am J Orthod Dentofacial Orthop.* 2007;132(3):332-339.
13. Leticia Ferreira dos santos, Rodrigo Galo, Ricardo Henrique Alves da silva. Gender evaluation in human beings by occlusal radiographs. *Braz. J. Oral. Sci.* 2015;14(1):23-26.
14. Dalidjan M, Sampson W, Townsend G. Prediction of dental arch development: an assessment of Pont's Index in three human populations. *Am J Orthod Dentofacial Orthop.* 1995; 107(5):465-75.