

Cone beam CT - A preferable imaging modality to diagnose stafne's bone cavity

Ajay Parihar^{1,*}, Ashish Saxena², Amit Rawat³, Nimesh Jain⁴

^{1,3}Associate Professor, ^{1,4}Dept. of Oral Medicine and Radiology, ²Dept. of Pedodontics, ³Dept. of Oral Surgery, ^{1,3}Government College of Dentistry, Indore, Madhya Pradesh, ⁴Private Practitioner, Indore, Madhya Pradesh, India

***Corresponding Author:**

Email: ajaycbct@gmail.com

Abstract

The Stafne's bone cavity is a depression of the mandible on the lingual surface. The Stafne defect is normal anatomical variant because of depression created by salivary gland tissue associated with the submandibular gland. Cone Beam Computed Tomography (CBCT) is newer radiological tool for diagnosing maxillofacial diseases and dental implant planning. The Stafne bony cavity is incidental finding in dental radiographs and CBCT. We are reporting five cases of Stafne bone cavity with pictures of CBCT to emphasize the preferable imaging modality for diagnosing Stafne's bone cavity.

Keywords: Stafne bone cavity, Static bone cavity, Stafne cyst, Idiopathic bone cavity.

Introduction

A series of 35 cases were reported first by Edward C. Stafne in 1942 which appears as radiolucent cavities in the posterior region of the mandible. The lesions were located between mandibular angle and the third molar region, beneath the inferior alveolar canal and superior to mandibular inferior border. A plethora of names has been given to this lesion like Stafne's bone cyst, lingual mandibular bone defect and lingual mandibular bone depression but the word "cyst" is a misnomer as it is not truly a cyst. Fluid contents have never, been reported. A more accurate term is "Stafne bone cavity" which was suggested by Barton et al in 1999.²

Most of the findings of Stafne bone cyst are based on intraoral dental films or orthopantographs. These two dimensional imaging techniques may not be conclusive when the lesion is in doubt. The Stafne bone cavities can be misdiagnosed for mandibular radiolucencies including traumatic bone cyst, periapical cyst, odontogenic keratocyst, fibrous dysplasia, non-ossifying fibroma, dmetastasis, vascular malformation, giant cell tumor, focal osteoporotic bone marrow defect, basal cell nevus syndrome, and the brown tumor of hyperparathyroidism.^{3,4}

Case Report 1:

A 65 year-old male patient referred to our diagnostic clinic for evaluation of radiolucent lesion in left angle of the mandible. A CBCT scan with smaller field of view (5cmmx5cmm) was performed in order to diagnosis of the lesion. Well circumscribed, oval shaped hypodense area observed in lingual surface of mandible, anterior to left angle of mandible, above the inferior cortex of mandible and below the mandibular canal which was diagnosed as Stafne's bone cavity. (Fig. 1) Information was given about the lesion and the patient is still in the follow-up course.

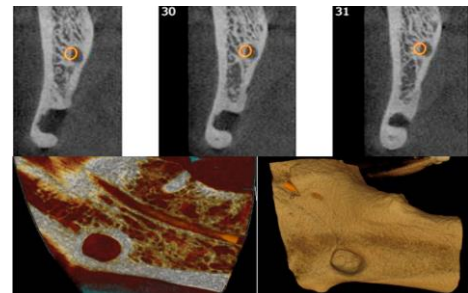


Fig. 1:

Case Report 2:

A 36 year-old male patient referred to our diagnostic clinic for evaluation inferior alveolar nerve and its relation with impacted right third molar. A CBCT scan with medium field of view (10cmmx5cmm) was performed, which revealed a incidental finding of a small radiolucent cyst like lesion below right third molar. CBCT showed a lingual bone depression at the level of the right mandibular third molar region. Mesioangually impacted 48 is observed. Solitary hypodense area noted at inferior cortex at the level of 48 suggestive of Stafne's bone cavity. (Fig. 2)

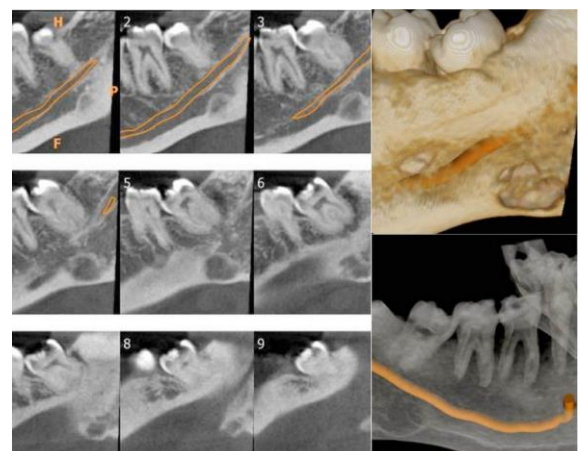


Fig. 2:

Case Report 3

A 69 year-old male patient referred to our diagnostic clinic for evaluation of radiolucent lesion in left angle of the mandible. A CBCT scan with smaller field of view (5cmmx5cmm) was performed in order to achieve the definitive diagnosis of the lesion. Well circumscribed, oval shaped hypodense area observed in lingual surface of mandible, anterior to left angle of mandible, above the inferior cortex of mandible and below the mandibular canal. This was the only case where we observed that there was thinning of bone on the buccal aspect too. Hence it was diagnosed as Stafne's bone cavity. (Fig. 3)

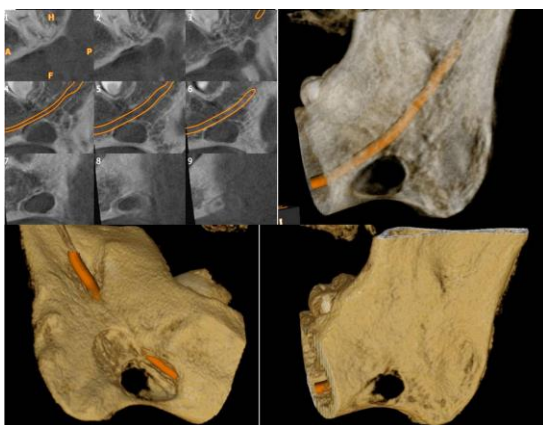


Fig. 3:

Case Report 4

A 57 year old female patient referred to our diagnostic clinic for evaluation of pain in right molar region of mandible. A CBCT scan with smaller field of view (5cmmx5cmm) was performed in order to achieve the definitive diagnosis of the lesion. At the inferior border of mandible on lingual surface in the region of 47; well define oval shaped depression observed which was causing thinning of cortical bone. The incidental finding was diagnosed as Stafne bone cavity. (Fig. 4)

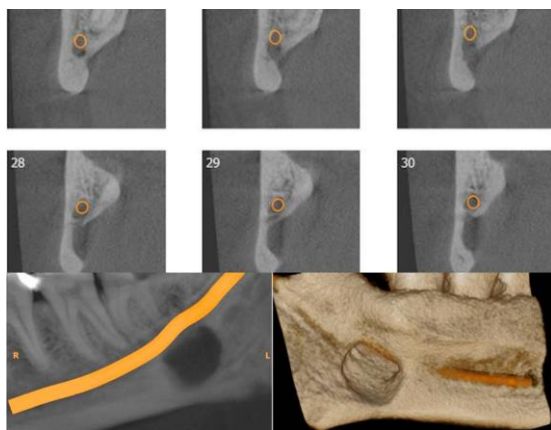


Fig. 4:

Case Report 5

A 52 year old female patient referred to our diagnostic clinic for evaluation of pain in right molar region of mandible. A CBCT scan with smaller field of view (5cmm x 5cmm) was performed in order to locate any contributing factors of her complaint. At the inferior border of mandible on lingual surface in the region of 47; well define oval shaped depression observed which was diagnosed as Stafne's bone cavity. (Fig. 5)

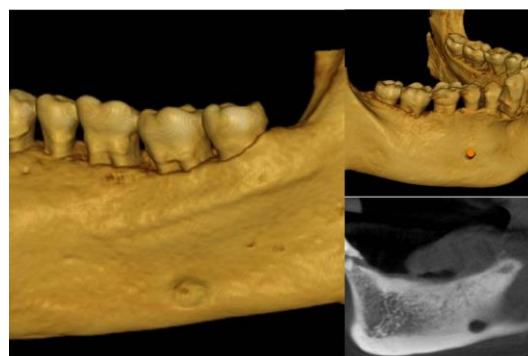


Fig. 5:

Discussion

Edward C Stafne firstly named Stafne bone defect after that numerous cases have been reported in different names like Stafne bone cavity, lingual mandibular bone defect, static bone cavity, idiopathic bone cavity and Stafne cyst.

Stafne bone cyst is asymptomatic and detected in routine radiographic examinations.⁵ It occurs in more commonly in men in comparison to women.⁶ In our cases 3 out of 5 were male patients. Stafne's bony cavity is positioned above or at the inferior border of the mandible, and interestingly always beneath the inferior alveolar canal. All of the cases seen through CBCT images were above the inferior border of mandible and beneath the inferior alveolar canal. In Case 3 and Case 4 the inferior alveolar canal is placed just above the Stafne's bony cavity, which was unique and can be attributed to the fact that the CBCT images has revealed better anatomic relationship of inferior alveolar canal and Stafne's bone cavity. CBCT is a high resolution, low radiation technique that provides accurate data on the shape and size of Stafne bone defect.⁷ Stafne bone defect has two types anterior and posterior type of Stafne's bone cavity. The posterior variant is most commonly observed. The submandibular gland is directly related with the posterior type of Stafne's bone cyst, the sublingual gland could be related with the anterior type.⁸

The pathogenesis of the Stafne's bony cavity is still unclear. It was originally postulated by Stafne⁹, that salivary gland becomes entrapped during the development and during the ossification of the mandible. However these defects are more frequently

diagnosed in adults rather than in children, hence the development of such lesions occurs later in life, after the ossification of the mandible. Philipsen proposed that progressive reduction in the mineralized bone volume after 40 years of age causes depressions radiographically.¹⁰ Other theories suggested for etiology for Stafne's bony cavity is because of pressure of the glandular tissue on the lingual cortex of the mandible causing a lingual bony depression.¹¹ Stafne's bony cavity can also result from benign fatty or vascular lesions.¹²⁻¹⁴ The clinical importance of diagnosing the Stafne's bony cavity is to differentiate from other pathologies of posterior mandible mimicking Stafne's bony cavity. Lack of clinical symptoms, buccolingual expansion and asymptomatic posterior teeth clinically as well as radiographically will help to differentiate these lesions from other similarly appearing pathologies. CBCT is useful in differentiating Stafne's bony cavity from other unilocular lesions like unicystic ameloblastoma, residual cyst, traumatic bone cyst, keratocystic odontogenic tumor, giant cell granuloma and focal osteoporotic defects of posterior mandible. Low radiation dose, less exposure time and better 3 dimensional images¹⁵ from CT make CBCT a preferable imaging modality to diagnose Stafne's bone cavity.

Conclusion

Stafne's bony cavity is incidental finding commonly seen in posterior mandible. CBCT is a preferable modality to diagnose and differentiate this cavity from other lesion of posterior mandible due to less radiation than CT, better anatomical picture and its relationship from adjacent structures in comparison to 2 dimensional imaging.

References

1. Stafne E. Bone cavities situated near the angle of the mandible J Am Dent Assoc 1942;29:1969-72.
2. Barton F, Branstetter, Jane L, Weissman, and Sheldon B. Kaplan. Imaging of a Stafne Bone Cavity: What MR Adds and Why a New Name Is Needed. AJNR Am J Neuroradiol 20:587-589, April 1999.
3. Prapanpoch S, Langlais RP. Lingual cortical defect of the mandible: an unusual presentation and tomographic diagnosis. Dentomaxillofac Radiol 1994;23:234-237.
4. Barak S, Katz J, Mintz S. Anterior lingual mandibular salivary gland defect: a dilemma in diagnosis. Br J Oral Maxillofac Surg 1993;31:318-320.
5. White SC, Pharoah MJ. Oral Radiology; principles and Interpretation. 6th ed. St. Louis: Mosby Inc; 2009. P. 574.
6. Etöz M, Etöz OA, Sahman H, Sekerci AE, Polat HB. An unusual case of multilocular Stafne bone cavity. Dentomaxillofac Radiol 2012;41:75-8.
7. Kopp S, Ihde S, Bienengraber V. Differential diagnosis of stafne idiopathic bone cyst with digital volume tomography (DVT). J Maxillofac Oral Surg 2010;9:80-1.
8. Quesada-Gómez C, Valmaseda-Castellón E, Berini-Aytés L, Gay-Escoda C. Stafne bone cavity: A retrospective study of 11 cases. Med Oral Patol Oral Cir Bucal.2006;11:E277-80.
9. Stafne EC. Bone cavities situated near the angle of the mandible. J Am Dent Assoc. 1942;29:1969-72.
10. Judit Herranz-Aparicio, Rui Figueiredo, Cosme Gay-Escoda Stafne's bone cavity: An unusual case with involvement of the buccal and lingual mandibular plates. J Clin Exp Dent. 2014;6(1):e96-9.
11. Boyle CA, Horner K, Cautlhwed P, Fleming GI. Multiple stafne bone cavities: A diagnosis dilemma, Dent update 2000;27:494-7.
12. Tsui SH, Chan FF. Lingual mandibular bone defect: case report and review of the literature Aust Dent J 1994;39:368-71.
13. Shimizu M, Osa N, Okamura K, Yoshiura K. CT analysis of the Stafne's bone defects of the mandible. Dentomaxillofac Radiol 2006;35:95-102.
14. Minowa K, Inoue N, Sawamura T, Matsuda A, Totsuka Y, Nakamura M. Evaluation of static bone cavities with CT and MRI. Dentomaxillofac Radiol 2003;32:2-7.
15. Diego Coelho Lorenzoni, Ana Maria Bolognese, Daniela Gamba Garib, Fabio Ribeiro Guedes, and Eduardo Franzotti Sant'Anna, "Cone-Beam Computed Tomography and Radiographs in Dentistry: Aspects Related to Radiation Dose," International Journal of Dentistry, vol. 2012, Article ID 813768, 10 pages, 2012. doi:10.1155/2012/813768.