

Radiographic study of the third molar in Senegalese population

NDIAYE Mamadou Lamine^{1,*}, SOUMBOUNDOU Sankoung², DIATTA Mamadou³, NDIAYE Fallou⁴,
TOURE Babacar⁵

¹⁻⁴Assistant Professor, ⁵Professor, ^{1,4}Service of Dento-Maxillofacial Radiology, ²Service of Conservative Dentistry, Endodontics, ³Service of Oral Surgery, ⁵Service of Conservative Dentistry, FMPO, Cheikh Anta Diop University of Dakar, Senegal

***Corresponding Author: NDIAYE Mamadou Lamine**

Email: mlndiaye04@gmail.com

Abstract

Aim: The aim was to study the status of the third molar in a Senegalese population using panoramic radiography.

Materials and Methods: The study covered 183 patients, aged 20 to 45 years, who came to the Department of Dentistry for consultation. After a clinical examination, each patient was given a panoramic x-ray. The variables of the third molar studied were: agenesis, impacted status, angle inclination of the third mandibular molar.

Results: Of the 732 third molars explored, 76.6% (n=561) were anatomically well implanted on the dental arch. The prevalence of agenesis of the third molar in the study sample was 6.9% (n=50) and it was higher at the maxillary with 7.1%. On the other hand, the third molars impacted represented 12.8% (n=94) and they were more important at the mandible with 13.7%. Extraction was more frequent in the third mandibular molar. Mesio-angulation was the most common pattern.

Conclusion: This study provided an overview of the prevalence of agenesis of the third molar and the value of panoramic radiography in the third molar study.

Keywords: Agenesis, Impacted tooth, Panoramic radiography, Third molars.

Introduction

The third molar is the last tooth to erupt in the dental arch. According to evolutionist theories, the third molars are normally disappearing teeth. These theories are argued by phylogenetic, genetic and epigenetic arguments. This explains why agenesis, which remains more frequent in the third molar than the rest of the other human teeth.^{1,2} The prevalence of agenesis of the third molar varies according to individuals and ethnicities. If it is not agenesis during its evolution, due to the lack of available space, it is impacted. The third molars impacted are often associated with pericoronitis, tumor-related or traumatic accidents.³ With the pains associated with dental flare-ups, accidents related to the evolution of the wisdom tooth are a very frequent reason for consultation. Extraction of the third molar is the most commonly used therapy for the management of disorders of the third molar.⁴ All these parameters reinforce the evolutionist theories that predict its disappearance. However, beyond its role in the diet, the third molar is of particular interest in age estimation.⁵

The aim of this present study was to evaluate, by panoramic radiography, the status of the third molar in a Senegalese population.

Materials and Methods

This study was conducted at the Department of Dentistry of the Faculty of Medicine, Pharmacy and Dentistry of the Cheikh Anta Diop University in Dakar, Senegal. The study included 183 Senegalese subjects randomly selected from among patients who came for consultation at the dental clinic between January and April 2018.

Criteria for Selections: To be included in the study, patients had to give their agreement to participate in the study, no history of bone surgeries involving posterior quadrants,

without systemic syndrome, know their dental history. Image distortions affecting the visualization of the third molar and the mandibular canal on panoramic radiographs as well as patients with a history of orthodontic treatment were excluded.

Methods: All participants had given their consent to conduct the study. A complete examination of the general condition and oral history of each subject, followed by an intraoral examination was performed by a qualified dental surgeon. Patients who met the criteria were subjected to a panoramic radiograph examination. The entire examination was performed by a Carestream CS 9000 3D X-ray machine. The radiographs were performed by an experienced radiology technician to minimize image distortion. The radiographs were performed according to ALARA standards "As Low as Reasonably Achievable" according to the CIPR (International Commission for Radiological Protection). The images were displayed directly on the computer screen on the image reading software, CS 3D imaging®. The study was authorized by the institution's ethics committee.

Radiographic Interpretations

Normal: If it is well implanted on the arch.

Agenesis: was considered agenesis, any third molar absent on the arch on intraoral examination and radiography without a history of dental avulsion.

Dental Extraction: the third molars absent in the mouth following a dental extraction confirmed by the patient.

Impacted: any third molar absent on the arch or partially extended and whose presence is confirmed by panoramic radiography.

Inclination Angle: The angle of inclination was assessed by measuring the angle between the major axis of the third mandibular molar and the major axis of the adjacent second

molar using Winter's classification, cited by Gupta et al⁶ (Fig. 1a,1b,1c,1d) as follows:

1. Vertical impaction: 10° to - 10°;
2. Mesio-angular impaction: 11° to 79°;
3. Disto-angular impaction: -11° to -79°;
4. Horizontal impaction: 80° to 100°;
5. Others: 111° to -80°.
6. Oral-lingual impaction.

The classification of unusual angulations such as "mesio-inverted", "disto-inverted" and "disto-horizontal" has been combined and referred to as "other".

Statistical Analysis

The data collected were subjected to statistical analysis using SPSS Version 20.0 data editing software (Microsoft Corporation Inc., Chicago, IL, USA). Results were expressed in numbers and percentages. The chi-square test was used to evaluate associations. The significant level was set at p <0.05.

Results

Of the 183 subjects, 71.6% (n=131) were male, with a sex ratio of 2.5. The average age of the sample was 23.8±2.3 years. A total of 732 third molars was explored. The prevalence of third molars absent on panoramic radiograph was 10.5% (n=77) (Table 1).

Of the 732 third molars explored, 76.6% (n=561) were anatomically well implanted on the dental arch. The prevalence of third molar agenesis in the study sample was 6.9% (n=50) (Fig. 1a). It was higher at the maxillary with 7.1% (n=13) for the 28 and 9.8% (n=18) for the 28, at the mandible with 5.5% (n=9) and 4.9% (n=9) respectively for the 38 and 48 (Table 2). Impacted third molars (Fig. 2-4) represented 12.8% (n=94). They were higher on the mandibular with 13.7% (n=25) on the left side and 16.9% (n=31) on the right side (Table 2). The third mandibular molars were the most extracted than the maxillary teeth (Table 2).

The Chi-square test showed that the status of each third molar agenesis, normal, extracted or impacted was not related to gender, p>,05 (Table 3).

According to Winter's classification, mesioangulation (Fig. 1a) was more frequent with 77.7% (n=24) for 38 and 90.9% (n=20) for 48 (Table 4).

Table 1: Distribution of the third molars according to their presence

Teeth	18	28	38	48	Total
	n (%)	n(%)	n(%)	n(%)	n(%)
Missing	17 (9.2)	21(11.5)	20 (11)	19 (10.3)	77 (10.5)
Present	166 (90.8)	162 (88.5)	163 (89)	164 (89.7)	655(89.5)
Total	183 (100)	183 (100)	183 (100)	183 (100)	732 (100)

Table 2: Distribution of third molars according to their status and tooth type

Teeth	18	28	38	48	Total
	n (%)	n (%)	n (%)	n (%)	n (%)
Normale	146 (79.8)	144 (78.7)	132 (72.1)	139 (76)	561 (76.6)
Impacted	20 (10.9)	18 (9.8)	31(16.9)	25 (13.7)	94 (12.8)
Agenesis	13 (7,1)	18 (9,8)	10 (5,5)	9 (4,9)	50 (6,9)
Extraction	4 (2.2)	3 (1.6)	10 (5.5)	10 (5.5)	27 (3.7)
Total	183 (100)	183 (100)	183 (100)	183(100)	732 (100)

Table 3: Status distribution of third molars by gender

Teeth	18		28		38		48	
	M n(%)	F n(%)	M n(%)	F n(%)	M n(%)	F n(%)	M n (%)	F n(%)
Normale	105 (25.8)	41 (26)	104 (25.5)	40 (26)	95 (23.3)	37 (24)	103 (25.3)	36 (23.4)
Impacted	14 (22.2)	6 (19.4)	11 (17.5)	7 (22.6)	22 (35)	9 (29)	16 (25.4)	9 (29)
Agenesis	11 (29)	2 (16.7)	14 (36.7)	4 (33.3)	7 (18.4)	3 (25)	6 (16)	3 (25)
Extraction	1 (6.2)	3 (25)	2 (12.5)	1 (8.3)	7 (43.7)	3 (25)	6 (37.7)	4 (33.3)
P	0.14		0.71		0.99		0.59	

M : male, F : Female

Table 4: Angle of inclination of the third mandibular molar according to Winter's classification (6)

Angle	38		48	
	n	%	n	%
Vertical	2	6.5		
Mésio-angular	24	77.4	20	90.9
Horizontal	5	16.1	5	9.1
Total	31	100	25	100

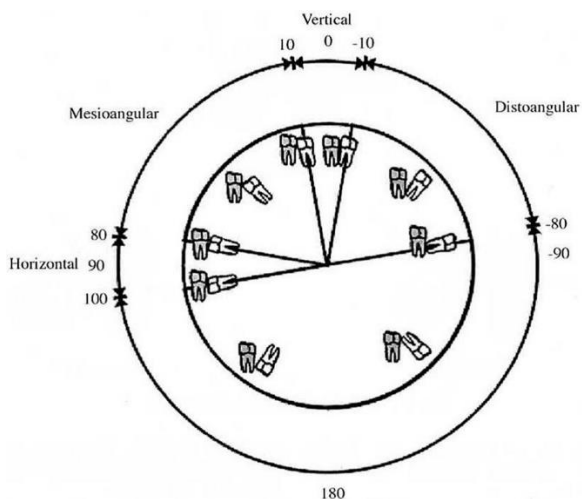


Fig. 1a: Winter classification cited by Gupta (6)

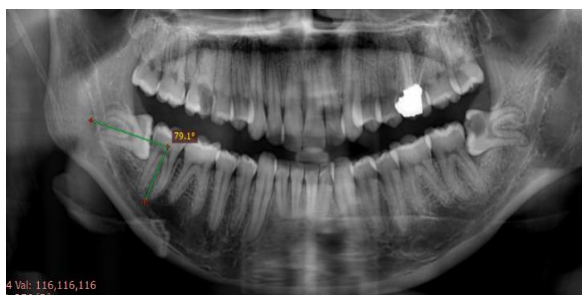


Fig. 1b : 48 horizontal impactation

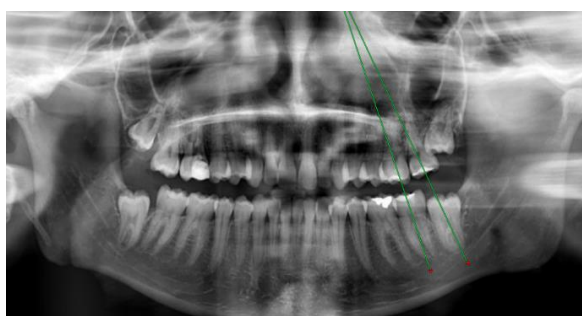


Fig. 1c : 38 vertical impactation

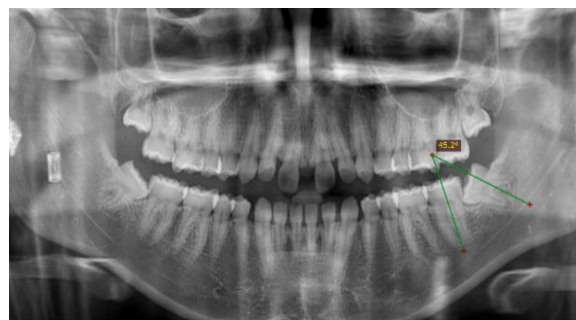


Fig. 1d: 38 impact in méso-angular impactation

Discussion

In this study, 89.5% of Senegalese had at least a third molar. This result was lower than the one found in the libyan population⁷ (93.5%) but lower than Sandu et al.⁸ (76%) in the Indian population¹. In a sample of 351 Turkish orthodontic patients, the prevalence of third molar agenesis in women and men was 5.7% and 7.2% respectively, with no statistically significant gender differences.¹ Levesque and al.⁵ report for French Canadians (9%), Hattab et al.⁹ for Jordanians (9.1%), Venta et al.¹⁰ for Finnish students (12%) and Kruger et al.¹¹ for the New Zealand population (15.2%). It was 16.8% in a Malaysian population, according to Goyal et al.¹² with a slight male predominance with no significant difference. It was lower in an Indian population (11.5%), Sandhu and al.⁸ with a prevalence among women of 12.8% and 8.3% among men. No difference in significance of the prevalence of agenesis by sex was noted. However, the prevalence of agenesis of the third molar in the Libyan population (5%) was lower than the results of this study.⁷ This difference confirms the thesis that agenesis varies according to ethnic groups and individuals but without any relation according to gender. The absence of the third molars on the dental arch can also be the result of a dental extraction.

Dental extraction is the most commonly used therapy in the management of the third molar. The reasons for extraction of the third molar are most often of infectious origin, such as decay and its complications, pericoronitis, and orthodontic indications.¹³ In this study, the prevalence of avulsed wisdom teeth was 3.7%. The third mandibular molars were the most extracted than the maxillary ones. Extraction of the third molars is the most commonly performed oral surgery¹² and surgical extraction of the third mandibular molars is the main cause of lower alveolar nerve injury^{14,15} which may be temporary or permanent.⁸ The anatomical situation of the mandibular canal in relation to the apexes of wisdom teeth varies greatly from one individual to another. Consequently, in some cases, it can compromise the surgical extraction of

these teeth. The risk of neurological complications after avulsion of the affected third mandibular molars increases considerably when there is contact between the apexes and a mandibular canal. neurological injury is often associated with a malpractice suit and a claim for compensation.¹

In this study, the prevalence of impacted was 12.8%. It was more important than the results of Gündüz et al.¹⁶ on Turkish subjects, which was 9.2%. However, the prevalence of impacted of the third mandibular molar was (15.2%) in Eritrea.¹⁷ Winter scale mesioangular impaction was the most common. According to Kaka et al.¹⁸ the mesioangular impaction position of the third ectopic molar is the most frequently encountered. This would be due to the eruption path of the third mandibular molars which are slightly inclined mesially, due to the thickness of the distal bone and the straightening curve.¹⁸ This predominance of mesioangular impaction can also be justified by delayed development and maturation, and lack of space at an advanced age.¹⁹ Our results were consistent with the following data; United States,²⁰ China,²¹ Spain²² where the most common type was mesioangular impaction. However, some studies show that vertical impaction is the most common.²³ This may be due to the fact that a different method of classifying angulation was used in these studies.

Panoramic radiography is limited because it provides a two-dimensional (2D) image of three-dimensional (3D) structures, with distortion of linear measurements and loss of definition due to superposition of underlying structures.²⁴ Thus, the limitations of the MC cannot be clearly distinguished in each panoramic examination.²⁵ In cases with signs of contiguity between the mandibular canal and the root of the third molar, further exploration with 3D radiography is indicated.

Conclusion

This study highlighted the prevalence of agenesis, extraction and impaction of the third molar in a Senegalese population. He also highlighted the diagnostic importance of panoramic radiograph in exploring the environment of the third molar. However, our study provides only preliminary data; therefore further multicenter and exhaustive studies are necessary.

Conflict of Interest: Nil.

References

- Celikoglu M, Kamak H. Patterns of third-molar agenesis in an orthodontic patient population with different skeletal malocclusions. *Angle Orthod.* 2012;82(1):165–169.
- Kaur B, Sheikh S, Pallagatti S. Radiographic assessment of agenesis of third molars and para-radicular third molar radiolucencies in population of age group 18-25 years old – A radiographic survey. *Arch Oral Res.* 2012;8:13–18.
- Obiechina AE, Arotiba JT, Fasola AO. Third molar impaction: evaluation of the symptoms and pattern of impaction of mandibular third molar teeth in Nigerians. *Odontostomatol Trop.* 2001;24:22–25.
- Chaparro-Avenida AV, Pérez-García S, Valmaseda-Castellón E, Berini-Aytés L, Gay-Escoda C. Morbidity of third molar extraction in patients between 12 and 18 years of age. *Med Oral Patol Oral Cir Bucal.* 2005;10(5):422–431.
- Levesque GY, Demirjian A, Tanguay R. Sexual dimorphism in the development, emergence, and agenesis of the mandibular third molar. *J Dent Res.* 1981;60:1735–1741.
- Gupta S, Bhowate RR, Nigam N, Saxena S. Evaluation of impacted mandibular third molars by panoramic radiography. *ISRN Dentistry.* 2011;2011:1–8.
- Byahatti S, Ingafou MS. Prevalence of eruption status of third molars in Libyan students. *Dent Res J (Isfahan).* 2012 ;9(2):152-7.
- Sandhu S, Kaur T. Radiographic evaluation of the status of third molars in the Asian-Indian students. *J Oral Maxillofac Surg.* 2005;63(5):640–645.
- Hazza's AM, Albashairh ZS, Bataineh AB. The relationship of the inferior dental canal to the roots of impacted mandibular third molars in Jordanian population. *J Contemp Dent Pract.* 2006;7(2):71–78.
- Venta I, Turtola L, Ylipaavalniemi P. Changes in clinical status of third molars in adults during 12 years of observation. *J Oral Maxillofac Surg.* 1999;57:386–389.
- Kruger E, Thomson WM, Konthasinghe P. Third molar outcomes from age 18 to 26: Findings from a population-based New Zealand longitudinal study. *Oral Surg Oral Med Oral Pathol Oral Radiol Endod.* 2001;95:150–155.
- Goyal S, Verma P, Raj SS. Radiographic Evaluation of the Status of Third Molars in Sriganganagar Population - A Digital Panoramic Study. *Malays J Med Sci.* 2016;23(6):103-112.
- Sebbar M, Bourzgui F. Predictive factors of third molar eruption. *Rev Stomatol Chir Maxillofac.* 2011;112(5):263-268.
- Tay AB, Zuniga JR. Clinical characteristics of trigeminal nerve injury referrals to a university centre. *Int J Oral Maxillofac Surg.* 2007;36:922–927.
- Tay AB, Go WS. Effect of exposed inferior alveolar neurovascular bundle during surgical removal of impacted lower third molars. *J Oral Maxillofac Surg.* 2004;62:592–600.
- Gündüz K, Acikgöz A, Egrioglu E. Radiologic investigation of prevalence, associated pathologies and dental anomalies of non-third molar impacted teeth in Turkish oral patients. *Chin J Dent Res.* 2011;14(2):141-146.
- Kumar VR, P Yadav, Kahsu E, Girkar F, Chakraborty R. Prevalence and Pattern of Mandibular Third Molar Impaction in Eritrean Population: A Retrospective Study. *J Contemp Dent Pract.* 2017;18 (2):100-106.
- Kaka L. Impacted mandibular third molar and the inferior alveolar canal in Iraqis (a radiographical study). *Iraq.* 2008;5(4):403.
- Hashemipour MA, Tahmasbi-Arashlow M, Fahimi-Hanzaei F. Incidence of impacted mandibular and maxillary third molars: a radiographic study in a Southeast Iran population. *Med Oral Patol Oral Cir Bucal.* 2013;18(1):e140-145.
- Bui CH, Seldin EB, Dodson TB. Types, frequencies, and risk factors for complications after third molar extraction. *J Oral Maxillofac Surg.* 2003;61(12):1379-1389.
- Quek SL, Tay CK, Tay KH, Toh SL, Lim KC. Pattern of third molar impaction in a Singapore Chinese population: a retrospective radiographic survey. *Int J Oral Maxillofac Surg.* 2003;32(5):548-552.
- Chaparro-Avenida AV, Pérez-García S, Valmaseda-Castellón E, Berini-Aytés L, Gay-Escoda C. Morbidity of third molar extraction in patients between 12 and 18 years of age. *Med Oral Patol Oral Cir Bucal.* 2005;10(5):422-431.
- Almendros-Marqués N, Berini-Aytés L, Gay-Escoda C. Influence of lower third molar position on the incidence of preoperative complications. *Oral Surg Oral Med Oral Pathol Oral Radiol Endod.* 2006;102(6):725-732.

24. Patel S, Dawood A, Whaites E, Pitt Ford T. New dimensions in endodontic imaging: part 1. Conventional and alternative radiographic systems. *Int Endod J.* 2009;42:447–62.
25. Kamrun N, Tetsumura A, Nomura Y, Yamaguchi S, Baba O, Nakamura S. Visualization of the superior and inferior borders of the mandibular canal: a comparative study using digital panoramic radiographs and cross-sectional computed tomography images. *Oral Surg, Oral Med, Oral Pathol, Oral Radiol.* 2013;115:550–557.

How to cite this article: Lamine N. M, Sankoung S, Mamadou D, Fallou N, Babacar T. Radiographic study of the third molar in Senegalese population. *Int J Maxillofac Imaging.* 2018;4(4):126-130.