

## Odontogenic keratocyst of mandible with an unusual presentation – A case report

Ramesh Gupta<sup>1,\*</sup>, Meenu Garg<sup>2</sup>, C. Anand<sup>3</sup>

<sup>1,2</sup>Associate Professor, <sup>3</sup>Senior Professor, <sup>1,3</sup>Dept. of Oral Medicine & Radiology, <sup>2</sup>Dept. of Prosthodontics, <sup>1,2</sup>Sudha Rustagi Dental College & Hospital, Faridabad, Haryana, <sup>3</sup>Maaruti Dental College, Bangalore, Karnataka India

**\*Corresponding Author: Ramesh Gupta**

Email: romesh\_gupta2002@yahoo.com

### Abstract

Odontogenic keratocysts (OKCs) are developmental odontogenic cysts of epithelial origin with aggressive behavior and a high recurrence rate. OKC can be formed in place of tooth, embrace the unerupted tooth, present in ascending ramus or present between roots of the teeth. OKC generally tends to grow in an anteroposterior direction within the medullary cavity of the bone without causing obvious bone expansion but in this case there was a large extra oral swelling along with extra oral sinus present. Hence OKC can be mistaken for any other cyst and tumour.

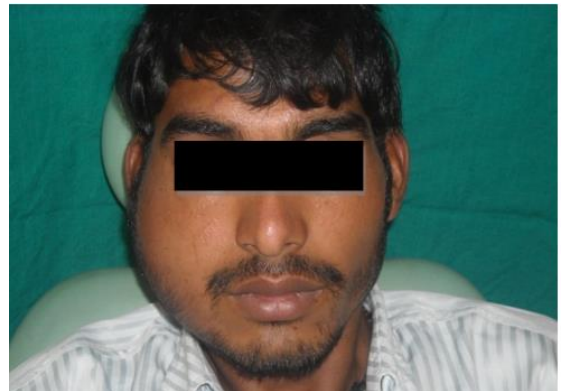**Keywords:** Odontogenic keratocysts, Unilocular.

### Introduction

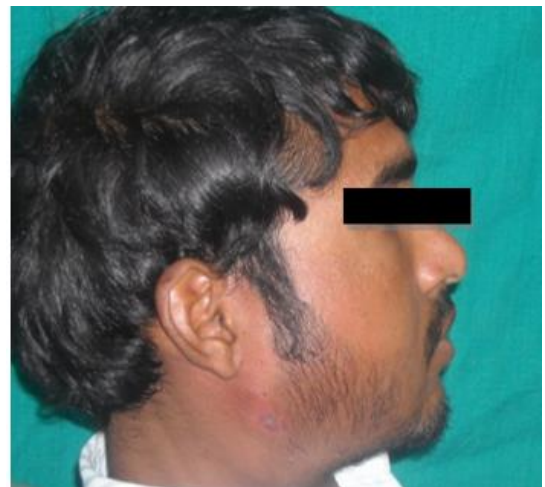Odontogenic keratocysts (OKCs) are developmental odontogenic cysts of epithelial origin with aggressive behavior and a high recurrence rate. It was first described by Phillipson in 1956, later in 1963 Pindborg and Hansen explained its histological criteria.<sup>1</sup> It was classified under developmental odontogenic cyst of jaw by WHO in 1971 & 1992, it was reclassified and renamed as keratocystic odontogenic tumor (KCOT) in the WHO classifications due to its aggressive behavior,<sup>2,3</sup> but later in 2017 it was again grouped into cystic lesion and reclassified in odontogenic keratocysts (OKCs).<sup>4</sup> OKC tends to grow in an anteroposterior direction within the medullary cavity of the bone without causing obvious bone expansion. Here we present a case report of OKC with a large extra oral swelling along with extra oral sinus.

### Case Report

22 year old male, patient reported to the Department of Oral Medicine, Diagnosis & Radiology with a chief complaint of swelling of middle and lower region on the right side of face since 6-8 months. His history Dates back to 9 months when he noticed a small swelling in lower right region of face. Which started of its own and gradually increased in size to attain the present size. Later the swelling regressed in size along with the formation of extra oral sinus. Now patient presented with a similar swelling at the same region of the face along with extra oral sinus. There was no history of trauma, numbness, or ulceration associated with the swelling. (Fig. 1, 2)



**Fig. 1: Front view**



**Fig. 2: Side view**

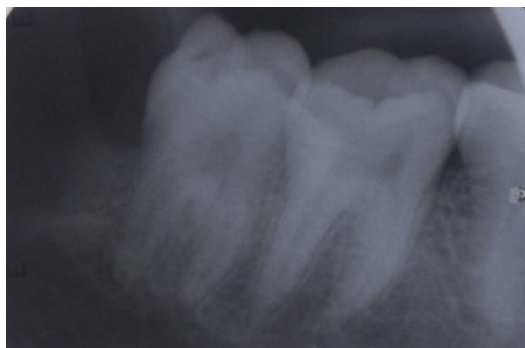

Fig. 3: Digital Iopar

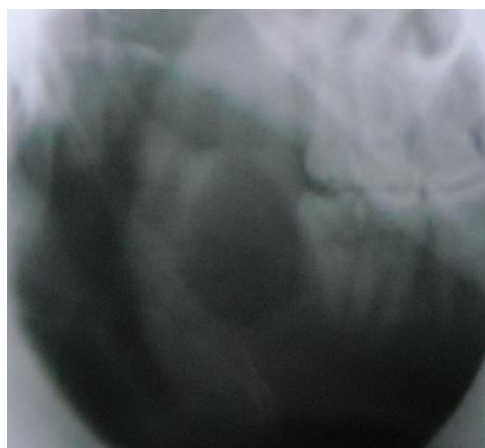


Fig. 4: LO ramus of mandible

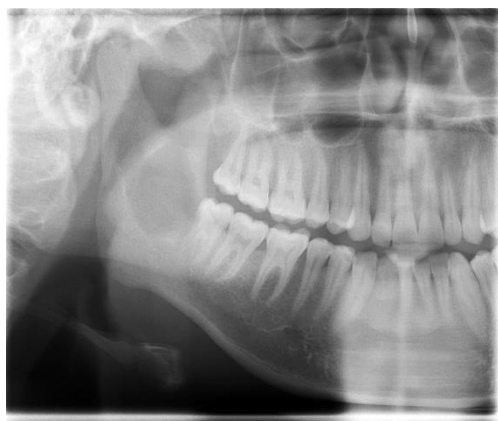

Fig. 5: Digital panoramic x-ray

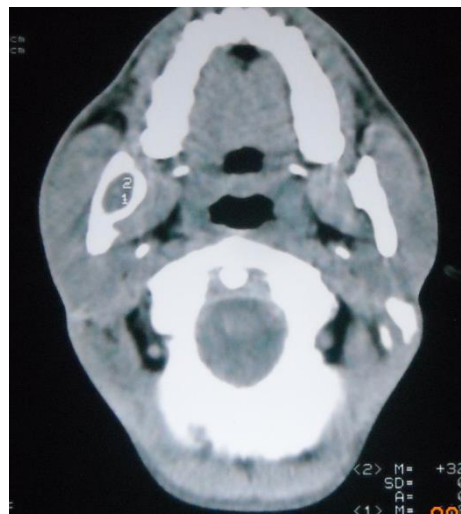


Fig. 6: Axial section of CT scan

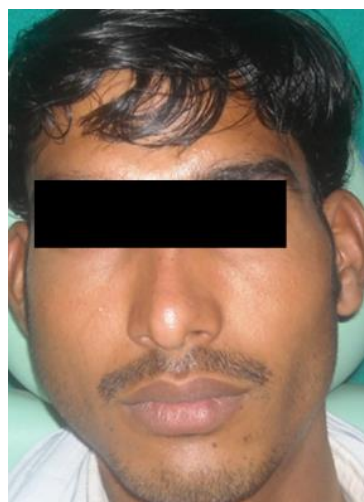

Fig. 7: Post operative front view

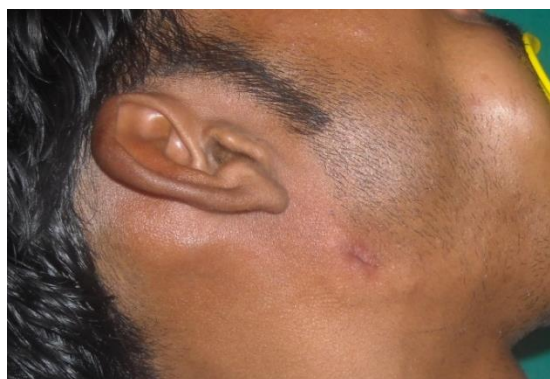

Fig. 8: Post operative side view

### On Extra Oral Examination

A unilateral round to ovoid swelling is present on the middle and lower 1/3 of face extending supero inferiorly from right infraorbital margin to lower border of the mandible and Mesio distally it extends from the mid pupillary line to 1 cm anterior to tragus of ear Swelling was same as color of the facial skin measuring about 9 x 8 cm in

size.. It has a smooth surface, well defined edges and skin over swelling is smooth. The swelling is non pulsatile with no movement present on respiration, coughing, deglutition, peristalsis and protrusion of tongue. There was a single extra oral sinus was present at 1cm inferior to the angle of the mandible on right side the face, on palpation inspeactory findings regarding the site shape, size and margins were confirmed. Swelling was firm to hard in consistency, tender, with slight rise in local temperature. Swelling has a smooth surface with clearly defined margins. Swelling was non fluctuant, not blanches on pressure, non compressible and no pulsations felt over the swelling, there was a single extra oral sinus was present 1cm inferior to the angle of the mandible on right side of the face on applying pressure from there was slight discharge of pus from the sinus. Right submandibular lymph nodes were tender and palpable.

On investigation teeth 46 47 48 were found to be vital IOPA showed intact lamina dura w.r.t 47, 48 there was unilocular radiolucent area present distal to third molar region there was no peri apical pathology evident. Lateral oblique of ramus of the mandible of right side shows well defined unilocular radiolucency which is extending from apical and middle third of lower third molar upto the 0.5 cm inferior to the sigmoid notch and posteriorly extending two third of the ramus of the mandible. Segmental digital OPG of right side shows unilocular radiolucency with well-defined and corticated border w.r.t ramus of the mandible which is extending from the apical and middle third of lower third molar upto the 0.5 cm inferior to the sigmoid notch and posteriorly extending two third of the ramus of the mandible, measuring 3x4 cm, CT scan in axial and coronal section shows a well-defined lytic lesion in the ramus region with a bony wall breach with mild homogenous soft tissue wall thickening with no periosteal reaction, (Fig. 3-6) excisional biopsy was done along with the extraction of 48, Biopsy section shows cystic lining showing basophilic, palisaded hyperchromatic basal cells with the reversal of polarity of nucleus, the epithelium was 5-6 cell thick with corrugated appearance and showing parakeratinization overlying mature stroma shows dense infiltration of inflammatory cells lined by stratified epithelium supported by connective tissue wall. Based on history, clinical presentation, radiographic and histopathological examination final diagnosis of infected odontogenic keratocyst given. Enucleation of the Cyst distal of 48 was done along with the extraction of 48 the patient was followed up after one month and the healing was found to be satisfactory with no tendency for recurrence. (Fig. 7, 8)

## Discussion

Pindborg & Hansen 1963: Describe the "keratocyst" as "any cyst in which keratin was found in large extent. Earlier it was considered as primordial cyst but later keratocysts were grouped under separate cystic entity arising from Dental lamina or its remnants or extension of basal cells of overlying epithelium.<sup>1</sup> Rate of growth of OKC varies from 2 to 14 mm a year with a average of 7 mm & become slower

with advancing age. Pathogenic mechanism that favor growth & expansion are high mitotic rate, Over expression of anti-apoptotic protein Bcl-2 and Matrix metalloproteinases (MMP-2& 9).<sup>5,6</sup> OKC can be formed in place of tooth, embrace the unerupted tooth, present in ascending ramous (away from tooth bearing areas) or present between roots of the premolar. OKC generally tends to grow in an anteroposterior direction within the medullary cavity of the bone without causing obvious bone expansion but in this case there was a large extra oral swelling along with extra oral sinus was present. Typical radiological feature of OKC are enlargement at the expense of medullary space. Mandibular OKC enlarge to fill the whole ramus Margins are densely sclerotic with scalloped out line termed as "cloudy milky way" or "Luminal Haze, most OKCs are unilocular, when the cyst is multilocular and located at the molar ramus area it may be confused to ameloblastoma. Maxillary lesion tend to be smaller & unilocular and 50% of cyst produce only buccal cortical expansion and they get infected most often,<sup>5-7</sup> Histologically the lining of epithelium is usually very thin and uniform in thickness with little or no evidence of rete ridges A well-defined basal cell layer, the component cells of which are cuboidal or columnar in shape and often in a palisaded arrangement There is a thin spinous cell layer which often shows a direct transition from basal cell layer The cells of the spinous cell layer frequently exhibit intracellular edema. Keratinisation is predominantly parakeratotic but it may be orthokeratotic. The keratin layer is often corrugated the fibrous cyst wall is generally thin and usually uninflamed multiple micro cysts or "daughter cysts in the connective tissue wall of a large keratocyst contribute to high rate of recurrence.<sup>6-8</sup>

The differential diagnosis for KCOT includes ameloblastoma, central giant cell granuloma, odontogenic myxoma, calcifying epithelial odontogenic cyst, and dentigerous cyst.<sup>6-8</sup> Nevroid basal cell carcinoma syndrome (Gorlin syndrome) is an autosomal dominant disease caused by mutation in PTCH tumor suppressor gene. In this patients have temporoparietal bossing, hypertelorism, mandibular prognathism and skeletal anomalies. The most important clinical feature is the predisposition to develop multiple basal cell carcinomas. The appearance of multiple odontogenic keratocysts is usually the first manifestation of the syndrome. Therefore, any patient with odontogenic keratocysts should be evaluated for this syndrome Surgical modalities of OKC includes curettage, enucleation, or with Cornoy's solution (cauterization) marsupialization of large multilocular cyst excision & immediate bone graft high.<sup>7,8</sup> Recurrence rate can be due to incomplete removal of OKC, Retention of daughter cyst, micro cyst or epithelial island in wall of the cyst and development of new OKC from basal layer of oral epithelial. Resection of OKC should be accomplished in a fashion similar to the resection of a benign tumour such as Ameloblastoma or Myxoma which includes the resection of entire field of recurrence.<sup>8-10</sup>

## Conclusion

OKCs should be one of the differential diagnoses for most of the unilocular or multilocular radiolucency with extra oral swelling present in the mandibular ramus region. The clinical, radiographic, and histopathological correlations are essential for proper patient treatment and followup, which will avoid any further complications, as it's highly aggressive with high recurrence rate.

**Conflict of Interest:** Nil.

## References

1. Philipsen HP. Keratocystic odontogenic tumour. In: Barnes L, Eveson JW, Reichart P, Sidransky D, editors. World Health Organization Classification of Tumours: Pathology and Genetics of Head and Neck Tumours. Lyon: IARC Press; 2005. p. 306-7.
2. Bhargava D, Deshpande A, Pogrel MA. Keratocystic odontogenic tumour (KCOT) - A cyst to a tumour. *Oral Maxillofac Surg.* 2012;16:163-170.
3. Barnes L, Eveson JW, Reichart P, Sidransky D, editors. Pathology and genetics of head and neck tumours. Lyon: IARC Press; 2005. WHO classification of tumours series.
4. El-Naggar, Adel K; Chan, John KC; Grandis, Jennifer R; Takata, Takashi; Slootweg, Pieter J, eds. (2017), WHO Classification of Head and Neck Tumours, WHO/IARC Classification of Tumours, 9 (4th ed.), Lyon, France: IARC Press, ISBN 978-92-832-2438-9.
5. Madras J, Lapointe H. Keratocystic odontogenic tumour: Reclassification of the odontogenic keratocyst from cyst to tumour. *Tex Dent J.* 2008;125:446-454
6. Grasmuck EA, Nelson BL. Keratocystic odontogenic tumor. *Head Neck Pathol.* 2010;4:94-96.
7. Neville BW, Damm DD, Allen CM, Bouquot JE. Oral and Maxillofacial Pathology. 2 nd ed. Philadelphia: Saunders; 2002. p. 595.
8. Motwani MB, Mishra SS, Anand RM, Degwekar SS, Bhowate RR. Keratocystic odontogenic tumor: Case reports and review of literature. *J Indian Acad Oral Med Radiol.* 2011;23:150-154.
9. Forssell K, Forssell H, Kahnberg KE. Recurrence of keratocysts. A long-term follow-up study. *Int J Oral Maxillofac Surg.* 1988;17:25-28.
10. Rajkumar GC, Hemalatha M, Shashikala R, Sonal P. Massive keratocystic odontogenic tumor of mandible: A case report and review of literature. *Indian J Dent Res.* 2011;22:181.

**How to cite this article:** Gupta R, Garg M, Anand C. Odontogenic keratocyst of mandible with an unusual presentation – A case report. *Int J Maxillofac Imaging.* 2018;4(4):144-147.