

CBCT assessment of relationship between maxillary sinus floor and maxillary posterior teeth: A retrospective study

Praveen Kumar^{1,*}, Balaji Pachipulusu², Poornima Govindraju³

¹Post Graduate Student, ²Professor & HOD, ³Professor, Dept. of Oral Medicine & Radiology, Rajarajeswari Dental College and Hospital, Bangalore, Karnataka, India

*Corresponding Author: Praveen Kumar

Email: praveen2007223@gmail.com

Abstract

Introduction: Aim of the study was to assess the relationship between maxillary sinus floor and maxillary posterior teeth.

Materials and Methods: Retrospectively 50 cone beam computed tomographic images in the age group of 20 to 60 years were procured from CBCT archives randomly, based on the inclusion and exclusion criteria set forth for the study.

Results: Palatal root of right maxillary 1st premolar was farthest & mesiobuccal root of maxillary right 2nd molar was nearest to maxillary sinus (MS). Mean thickness of the distobuccal root for left maxillary 2nd molar with buccal cortical was maximum whereas mean thickness for the mesiobuccal root with buccal cortical plate for left maxillary 1st molar was minimum.

Conclusion: Adequate radiographic investigations are required before any surgical procedure in maxillary posterior teeth region. We recommend to use CBCT a 3-dimensional imaging modality when required.

Keywords: Cone beam computed tomography (CBCT), Maxillary posterior teeth, Maxillary sinus floor (MSF).

Introduction

During endodontic treatment, extraction and implant placement involving maxillary posterior teeth which are in close proximity to maxillary sinus (MS), the anatomical relationship between the floor maxillary sinus floor (MSF) and maxillary posterior teeth always pose a challenge in dentistry. Spread of infection from periapical region to MS can appear as a consequence of iatrogenic perforation as sinusitis.¹⁻³ It is affected by thickness of alveolar cortical plate and position of roots of maxillary posterior teeth in relation to MSF & determines the treatment planning.³⁻⁶

Imaging modalities involving conventional 2-dimensional radiography like intra oral periapical radiograph, panoramic radiograph & advanced imaging 3-dimensional radiography like CT imaging and CBCT have been used. CBCT is a preferred 3D imaging modality in maxillofacial region since it is a volumetric imaging modality which is ideal for capturing anatomic structures with less radiation exposure, cost effective, shorter acquisition time than CT. Hence, this study was undertaken with an aim to assess the relationship between MSF and maxillary posterior teeth using CBCT.

Materials and Methods

After getting approval from the institutional ethical committee the present study was conducted. 50 CBCT scans of bilateral maxilla were retrieved from the database after excluding the subjects with pathologies such as cysts, tumors, bone loss in maxillary posterior teeth region, evidence of fracture in maxillary posterior teeth region, showing errors and artifacts obscuring visibility of structures in the maxilla.

Radiographic Investigation

All images were assessed and measured using ONDEMAND 3D and Scanora software of the CBCT

machine. Vertical relationship were classified into four types based on cross-sectional images.^{2,3} In built measurement tools were used to measure the distances. Bone thickness were measured to the corresponding alveolar cortical plate using CBCT.

Type 0: Location of MSF above root tip.

Type 1: MSF touches the root apex.

Type 2: MSF interposed between roots.

Type 3: Apical protrusion over the MSF.

Type 1 and type 3, were further classified into three types^{2,3}

Type B: MSF lowest point located on the buccal root.

Type BP: MSF lowest point located between the buccal and palatal roots.

Type P: MSF lowest point located on the palatal side of the palatal root.

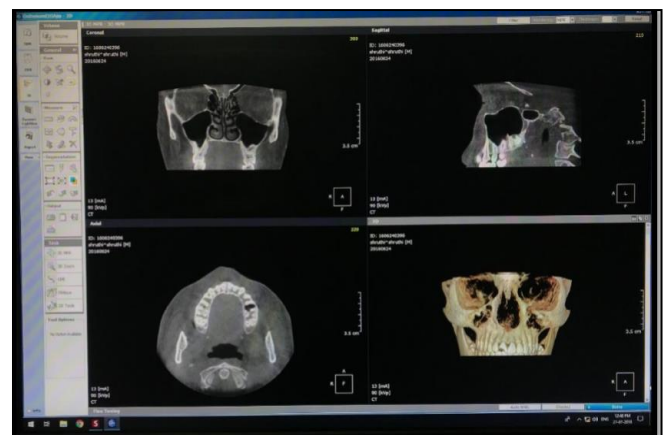


Fig. 1: ONDEMAND software showing coronal view, sagittal view, axial view and 3D view

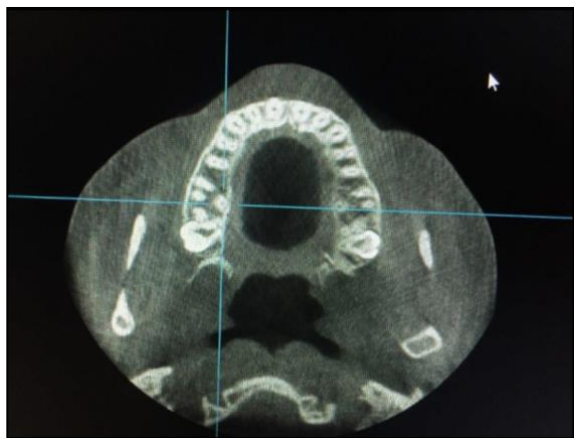

Fig. 2: Selection of the tooth (maxillary posterior tooth) in cross sectional view

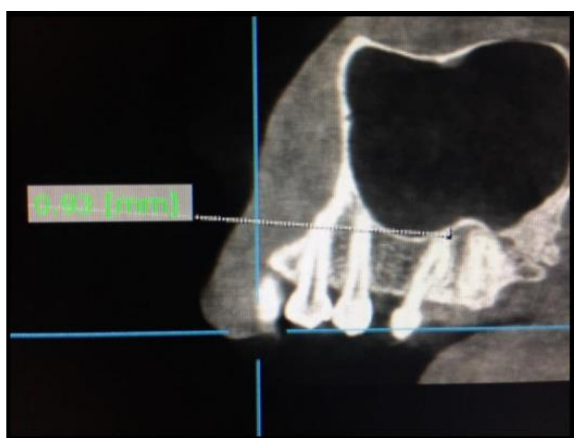

Fig. 3: Calculation of the vertical relationship between maxillary sinus floor and root of maxillary posterior tooth in sagittal view

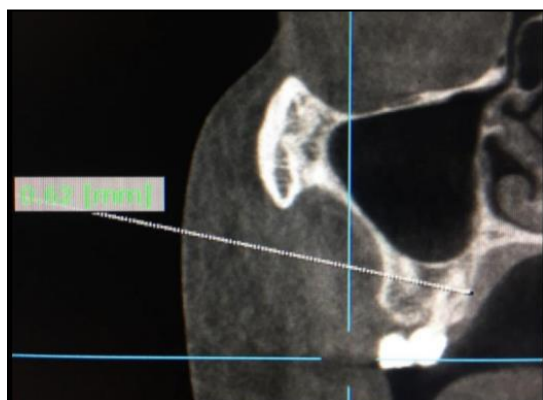


Fig. 4: Calculation of the thickness of respective cortical plate of maxillary posterior tooth in axial view

Reliability

Statistical analysis was performed using SPSS for Windows, version 22.0. Released 2013. Armonk, NY: IBM Corp. Interrater reliability assessment between Rater-1 & Rater-2 for assessment of distance (in mm) was estimated using Intraclass Correlation Coefficients. P<0.05, was set as the level of significance [P Value].

Results

Intra and inter observer performances had moderate to excellent reliability with Intra class Coefficient ranging from 0.63 to 0.95. According to our study findings type 0 was most common in maxillary 1st premolars whereas type 3 was more common in maxillary 1st and 2nd molar (Table 2). Comparing the mean distance of different maxillary posterior teeth root to MSF between right & left side there was no significant difference (Table 3). Palatal root of right maxillary 1st premolar was farthest whereas mesiobuccal root of right 2nd molar was nearest to MS (Table 3). Comparing the mean thickness of respective cortical plate of maxillary posterior teeth between left & right side there was no significant difference (Table 4). Mean thickness of the distobuccal root for left maxillary 2nd molar with buccal cortical was maximum whereas mean thickness for the mesiobuccal root with buccal cortical plate for left maxillary 1st molar was minimum (Table 4).

Discussion

Among all paranasal sinuses the maxillary sinus (MS) is the largest sinus. In adults the extension of the MS is variable. Due to the close relationship between MSF and roots of maxillary posterior teeth accidental oro-antral communication can occur. Awareness among clinicians of the relationship between the roots of the maxillary posterior teeth and MSF is must.¹⁻⁷ According to our study findings type 0 was most common in maxillary 1st premolars whereas type 3 was more common in maxillary 1st and 2nd molar (Table 2). Our study findings were in accordance with studies conducted by Abbas Shokri et al,² Yun- Hoa et al³and Fry et al.⁸ Comparing the mean distance of different maxillary posterior teeth root to MSF between right & left side there was no significant difference (Table 3). Findings were in accordance with studies conducted by Abbas Shokri et al,² Fry et al,⁸ Kilic et al.⁹ Palatal root of right maxillary 1st premolar was farthest whereas mesiobuccal root of maxillary right 2nd molar was nearest to MS (Table 3). Comparing the mean thickness of respective cortical plate of maxillary posterior teeth between left & right side there was no significant difference (Table 4). Our study findings were in accordance with studies conducted by Abbas Shokri et al,² Fry et al,⁸ Kilic et al.⁹ Mean thickness of the distobuccal root for left maxillary 2nd molar with buccal cortical was maximum whereas mean thickness for the mesiobuccal root with buccal cortical plate for left maxillary 1st molar was minimum (Table 4). Small sample size limits interpretation of our finding. Further investigation in large sample size would be necessary to confirm our findings.

Table 1: Age wise distribution among study subjects

Variables	Category	n	%
Age	15-30 yrs	31	62%
	31-45 yrs	14	28%
	46-60 yrs	5	10%

Table 2: Distribution of vertical relationship of maxillary sinus with respect to different maxillary teeth

Tooth No.	Type 0		Type 1B		Type 1P		Type 1 BP	
	n	%	n	%	n	%	n	%
Rt. 1PM	48	96%	1	2%	1	2%	0	0%
Rt. 2PM	29	58%	10	20%	4	8%	6	12%
Rt. 1M	21	42%	10	20%	1	2%	8	16%
Rt. 2M	14	28%	11	22%	3	6%	10	20%
Lt. 1PM	45	90%	0	0%	5	10%	0	0%
Lt. 2PM	26	52%	9	18%	4	8%	10	20%
Lt. 1M	13	26%	11	22%	5	10%	12	24%
Lt. 2M	18	36%	12	24%	0	0%	12	24%

Table 2: Distribution of vertical relationship of maxillary sinus with respect to different maxillary teeth

Tooth No.	Type 2		Type 3B		Type 3P		Type 3BP	
	n	%	n	%	n	%	n	%
Rt. 1PM	0	0%	0	0%	0	0%	0	0%
Rt. 2PM	0	0%	0	0%	1	2%	0	0%
Rt. 1M	2	4%	3	6%	3	6%	2	4%
Rt. 2M	4	8%	3	6%	1	2%	4	8%
Lt. 1PM	0	0%	0	0%	0	0%	0	0%
Lt. 2PM	0	0%	1	2%	0	0%	0	0%
Lt. 1M	1	2%	2	4%	3	6%	3	6%
Lt. 2M	0	0%	1	2%	2	4%	5	10%

Table 3: Comparison of mean distance (in mm) from different maxillary posterior teeth root apex to maxillary sinus b/w right & left side

Root	Tooth No.	N	Mean	SD	Mean Diff	Z	P-Value
Buccal	Rt. 1PM	50	5.65	3.52	-0.39	-1.064	0.29
	Lt. 1PM	50	6.05	2.85			
Palatal	Rt. 1PM	49	6.34	3.71	0.19	-0.415	0.68
	Lt. 1PM	49	6.15	3.50			
Buccal	Rt. 2PM	50	2.78	2.78	0.15	-0.617	0.54
	Lt. 2PM	50	2.63	2.98			
Palatal	Rt. 2PM	33	3.35	4.10	0.36	-0.589	0.56
	Lt. 2PM	33	2.99	2.87			
M. Buccal	Rt. 1M	50	1.38	2.22	-0.27	-1.081	0.28
	Lt. 1M	50	1.65	2.49			
D. Buccal	Rt. 1M	50	1.45	1.70	-0.15	-0.281	0.78
	Lt. 1M	50	1.59	2.08			
Palatal	Rt. 1M	50	2.85	3.09	0.41	-1.657	0.10
	Lt. 1M	50	2.44	2.96			
M. Buccal	Rt. 2M	50	0.75	1.41	-0.14	-0.356	0.72
	Lt. 2M	50	0.89	1.32			
D. Buccal	Rt. 2M	44	1.15	1.52	-0.13	-0.063	0.95
	Lt. 2M	44	1.28	2.00			
Palatal	Rt. 2M	50	1.98	2.79	-0.16	-0.383	0.70
	Lt. 2M	50	2.14	2.30			

Table 4: Comparison of mean thickness of respective cortical plate (in mm) of different maxillary posterior teeth root b/w right & left sides

Root	Tooth No.	N	Mean	SD	Mean Diff	Z	P-Value
Buccal	Rt. 1PM	49	0.89	0.53	-0.01	-0.338	0.74
	Lt. 1PM	49	0.90	0.60			
Palatal	Rt. 1PM	48	0.94	0.67	-0.03	-0.373	0.71
	Lt. 1PM	48	0.97	0.59			
Buccal	Rt. 2PM	48	1.25	0.87	0.09	-0.947	0.34
	Lt. 2PM	48	1.16	0.74			
Palatal	Rt. 2PM	39	1.02	0.75	-0.08	-0.098	0.92
	Lt. 2PM	39	1.10	0.65			
M. Buccal	Rt. 1M	50	0.88	0.66	0.14	-1.663	0.10
	Lt. 1M	50	0.75	0.48			
D. Buccal	Rt. 1M	50	1.08	0.64	0.00	-0.574	0.57
	Lt. 1M	50	1.08	0.68			
Palatal	Rt. 1M	50	1.06	0.60	0.11	-1.994	0.06
	Lt. 1M	50	0.94	0.54			
M. Buccal	Rt. 2M	50	1.38	0.86	0.14	-1.389	0.17
	Lt. 2M	50	1.24	0.83			
D. Buccal	Rt. 2M	44	1.38	0.66	-0.02	-0.15	0.88
	Lt. 2M	44	1.39	0.81			
Palatal	Rt. 2M	50	1.19	0.73	-0.02	-0.344	0.73
	Lt. 2M	50	1.21	0.89			

Table 5: Inter rater reliability assessment between rater-1 & rater-2

Teeth	Root	Distance				Thickness			
		ICC	95% CI		P-Value	ICC	95% CI		P-Value
			Lower	Upper			Lower	Upper	
Rt. 1PM	Buccal	0.76	0.36	0.94	0.002*	0.73	0.41	0.95	0.004*
	Palatal	0.72	0.22	0.92	0.007*	0.69	0.18	0.91	0.009*
Rt. 2PM	Buccal	0.79	0.37	0.95	0.002*	0.80	0.47	0.92	0.005*
	Palatal	0.85	0.78	0.99	0.001*	0.72	0.60	0.93	0.008*
Rt. 1M	M. Buccal	0.81	0.70	0.98	<0.001*	0.76	0.58	0.98	0.007*
	D. Buccal	0.75	0.43	0.91	0.004*	0.74	0.59	0.91	0.002*
	Palatal	0.71	0.38	0.90	0.008*	0.70	0.43	0.97	0.009*
Rt. 2M	M. Buccal	0.80	0.47	0.92	0.005*	0.65	0.21	0.89	0.01*
	D. Buccal	0.63	0.03	0.90	0.02*	0.73	0.59	0.95	0.003*
	Palatal	0.83	0.55	0.95	<0.001*	0.68	0.19	0.90	0.02*
Lt. 1PM	Buccal	0.77	0.41	0.94	0.001*	0.84	0.33	0.97	<0.001*
	Palatal	0.72	0.26	0.92	0.005*	0.70	0.34	0.96	0.008*
Lt. 2PM	Buccal	0.81	0.49	0.95	<0.001*	0.79	0.46	0.98	0.001*
	Palatal	0.76	0.37	0.93	0.002*	0.88	0.57	0.99	<0.001*
Lt. 1M	M. Buccal	0.88	0.69	0.97	<0.001*	0.67	0.23	0.99	0.01*
	D. Buccal	0.94	0.85	0.98	<0.001*	0.63	0.39	0.95	0.03*
	Palatal	0.69	0.18	0.91	0.009*	0.72	0.34	0.96	0.002*
Lt. 2M	M. Buccal	0.89	0.70	0.97	<0.001*	0.77	0.73	0.96	0.001*
	D. Buccal	0.95	0.86	0.99	<0.001*	0.72	0.55	0.96	0.001*
	Palatal	0.79	0.45	0.94	<0.001*	0.79	0.48	0.93	0.001*

*Statistically Significant

Note: ICC - Intraclass Correlation Coefficient

ICC values <0.50 - Poor reliability

0.50 - 0.75 - Moderate reliability

0.75 - 0.90 - Good reliability

> 0.90 - Excellent reliability

Abbreviation's- Lt.- Left, Rt.- Right, PM- Premolar, M- Molar, M. Buccal- Mesio Buccal, D. Buccal- Disto Buccal

Conclusion

The present study showed that palatal root of maxillary right 1st premolar was farthest from MSF and mesiobuccal root of maxillary right 2nd molar was nearest. Mean thickness of buccal cortical plate from distobuccal root of maxillary left 2nd molar was maximum & mesiobuccal root of maxillary left 1st molar was minimum. In comparing the mean distance between maxillary posterior teeth root apex to MSF & mean thickness of respective cortical plate of right and left side there was no significant difference. Adequate radiographic investigations are required before any surgical procedure in maxillary posterior teeth region. We recommend to use CBCT a 3-dimensional imaging modality when required. To concretely ascertain observations in our study, use of larger sample size is recommended and further studies can be conducted.

Conflict of Interest: None.

References

1. Von Arx T, Fodich I, Bornstein MM. Proximity of premolar roots to maxillary sinus: A radiographic survey using cone-beam computed tomography. *J Endod* 2014;40:1541-8.
2. Shokri A, Lari S, Yousefi F, Hashemi L. Assessment of the relationship between the maxillary sinus floor and maxillary posterior teeth roots using cone beam computed tomography. *J Contemp Dent Pract* 2014;15:618-22.
3. Jung YH, Cho BH. Assessment of the relationship between the maxillary molars and adjacent structures using cone beam computed tomography. *Imaging Sci Dent* 2012;42:219-24.
4. Fuhrmann R, Bücke A, Diedrich P. Radiological assessment of artificial bone defects in the floor of the maxillary sinus. *Dentomaxillofac Radiol* 1997;26:112-6.
5. Misch CE. Contemporary implant dentistry. 2nd ed. St. Louis: CV Mosby Co, 1999:76-194.
6. Maloney PL, Doku HC. Maxillary sinusitis of odontogenic origin. *J Can Dent Assoc* 1968;34:591-603.
7. Georgiev T, Peev S, Arnautska H. Relationship between root apices of maxillary posterior teeth and the maxillary sinus floor in patients from the Varna region. *Med Inform* 2015;4:30009.
8. Fry RR, Patidar D, Goyal S, Malhotra A. Proximity of maxillary posterior teeth roots to maxillary sinus and adjacent structures using Denta scan. *J Dent* 2016;7:126-30.
9. Kilic C, Kamburoglu K, Yuksel SP, Ozen T. An assessment of the relationship between the maxillary sinus floor and the maxillary posterior teeth root tips using dental cone-beam computerized tomography. *Eur J Dent* 2010;4(4):462-7.

How to cite this article: Kumar P, Pachipulusu B, Govindraj P. CBCT assessment of relationship between maxillary sinus floor and maxillary posterior teeth: A retrospective study. *Int J Maxillofac Imaging* 2019;5(1):10-4.