

Parasitic cyst of cheek! A rare but considerable differential diagnosis: An ultrasonography and color Doppler guided case report

Shakuntala Soujanya V^{1,*}, Harshavardhan², Suresh Kumar M³, Prabhakar Rao⁴

¹Assistant Professor, ^{2,3}Professor, ⁴Dental Surgeon, ^{1,2}Dept. of Oral Medicine and Radiology, ³Dept. of Oral and Maxillofacial Surgery, ¹⁻³Meghna Institute of Dental Sciences, Telangana, ⁴Sun Dental Care, India

***Corresponding Author: Shakuntala Soujanya V**

Email: shakuntalasoujanya@gmail.com

Abstract

The occurrence of parasitic cysts in head and neck region occurs by chance where it is commonly seen in people with varying dietary habits and life style but when it comes to oral cavity particularly buccal mucosa its preponderance is very rare and most of the times it gets confused with many of its similar group of lesions such as lipoma, mucocele, hemangioma, etc. It's the specific investigations like ultrasonography, FNAC and biopsy which finally helps in making systematic diagnosis of these parasitic cysts. These article focuses on reporting one of such a kind of case report.

Keywords: Asymptomatic swelling, Cheek region, Lipoma, Sialography, Ultrasonography, Color Doppler, Biopsy.

Introduction

Even though intra-oral parasitic infection is very rare, it can be included in the differential diagnosis, when patient presents with a firm submucosal nodule without overlying inflammatory signs which does not completely respond to routine therapy, especially in patients from endemic areas with varying dietary habits and lifestyle.¹ Prevalence of this disease is increasing day by day and emerging as a significant health problem in recent years in different areas of the world.² Hence a thorough knowledge of this varied parasitic infections of the oral cavity is very much essential for an oral healthcare professional to diagnose it and differentiate it from other varied benign group of lesions and treat accordingly.³ Here we are presenting such a case report with its rare occurrence in buccal mucosa.

Case Report

A female patient of age 45 years reported to regular dental OPD with a the chief complaint of swelling of right cheek of the face from 1 month which started initially as a small swelling of size of a peanut which gradually increased in its size to the attain existing dimensions then there it was with no other significant medical, dental and personal history and any deleterious habits. On thorough clinical examination a measurable roughly ovoid swelling of 3 X 2cm was appreciated extra orally in right cheek which was soft in consistency, immobile, non- tender on palpation with pinchable overlying skin and non-palpable lymphnodes bilaterally. Then intra orally, an ovoid swelling was seen in the right buccal mucosa measuring 1 X 0.5 cm approximately extending anteroposteriorly from mesial of 16 to distal of 17 and superoinferiorly on either side of occlusal plane 0.5cm above and below of it with normal and smooth overlying mucosa which on plapation was soft in its consistency, non- tender with well-defined borders.

Before proceeding with the other necessary investigations an initial aspiration was done to rule out cystic lesions but a straw colour fluid was drawn and a later OPG and sialography were done where pathology involving

bone and parotid gland were ruled out. Then an ultrasonography and color Doppler of the lesion were done which revealed muscle bulk region, 16X16mm cyst sol with peri cyst hypoechoic thickening noted. On color Doppler mild peripheral vascularity noted suggestive of Muscle cyst or Muscle parasitic cyst. Based on these findings when a further history regarding her dietary habits were taken she revealed the habit of consuming pork.

Finally, the complete surgical excision of the lesion was done and the histopathological examination using H and E staining of soft tissue section revealed a cystic space lined by thick collagenous fibrous capsule surrounded by dense focal inflammatory cell aggregates chiefly lymphocytes, plasma cells and macrophages with extension into surrounding muscle suggesting a probable "Parasitic Cyst", but its variant was not confirmed since there is no evidence of larval forms within cystic space.

Discussion

The word parasitic cyst is a broad term which includes infections like Hydatid cyst caused by Echinococcus,⁴ Cysticercosis caused by Taenia Solium,³ Dilofilariasis,¹ etc.,. Even though the occurrence of these infections is very rare in the oral cavity it has gained its significance as they are the most common diseases occurring worldwide, with an estimated prevalence of more than 50 million individuals getting infected annually.⁵ It has varied site predilection of occurrence involving the oral mucosa, lips, gums, tongue, masseter muscle, etc. as solitary or multiple lesions.⁶

The disease is said to be commonly encountered in the 4th to 5th decade of life while showing significant female predilection.⁷ The humans gets effected or transmitted by eggs or larval form of these parasites when they consume food and water contaminated by them or by a bite of mosquito carrying them as vector or by consuming a pork or beef which acts as intermediate host for these parasites.^{8,9} Finally these individuals' acts as intermediate hosts where further development of these larval forms occurs and now enters into lymphatic or vascular circulation lodging in

certain favourable areas of tissue thus forming parasitic cyst.¹⁰

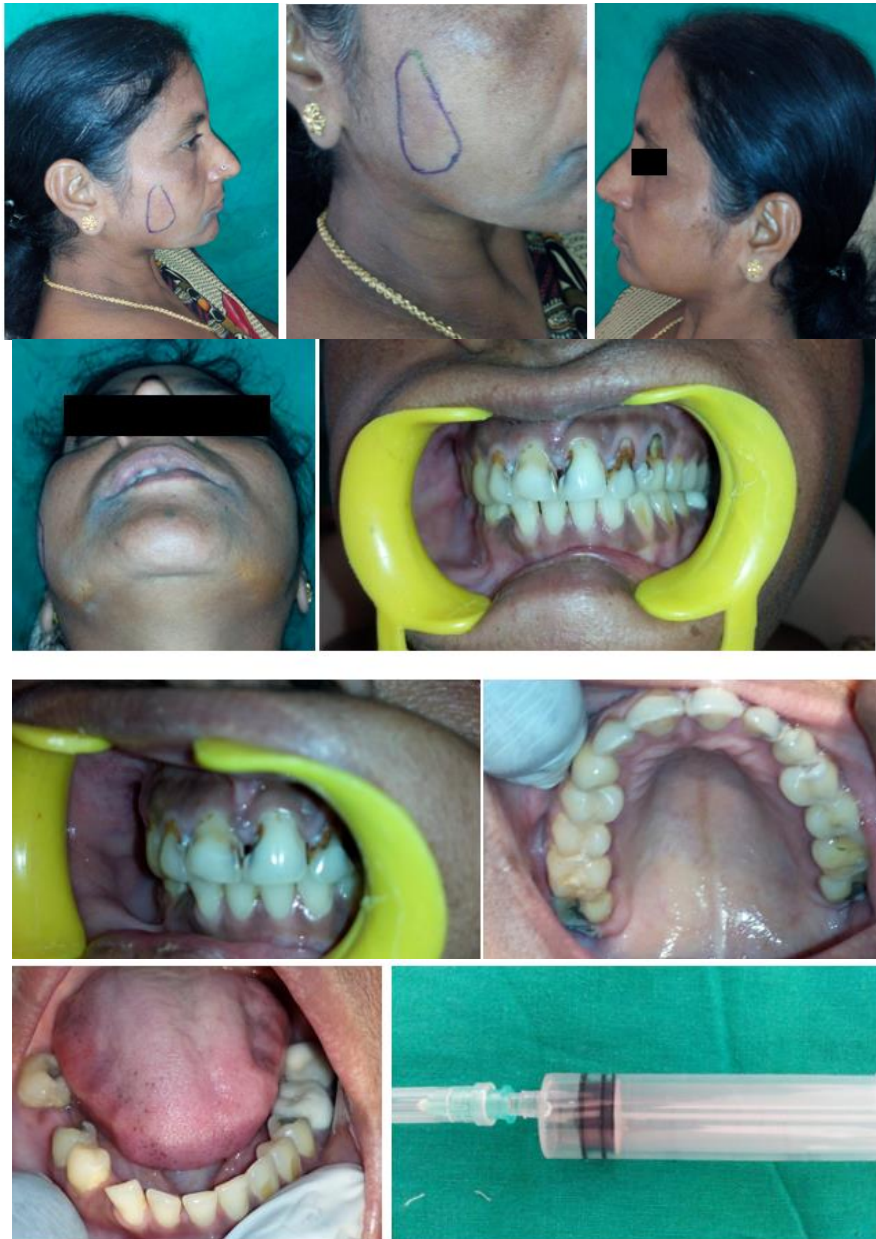

Fig. 1: Pre-Op

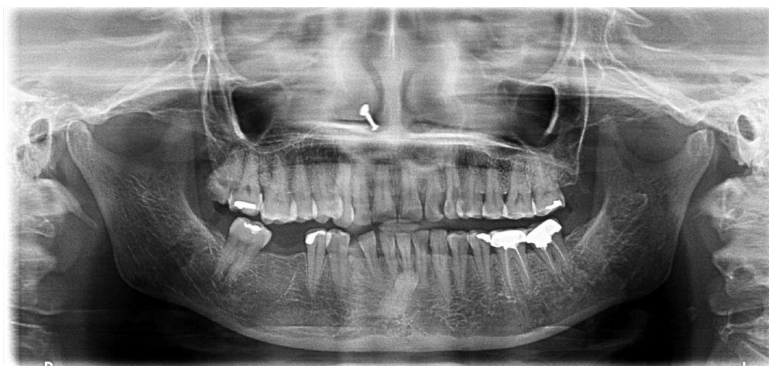

Fig. 2: Orthopantomograph

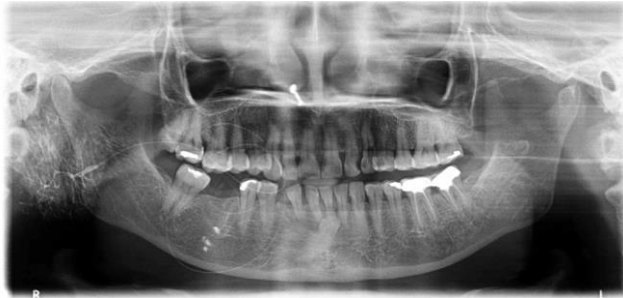

Fig. 3: Sialograph

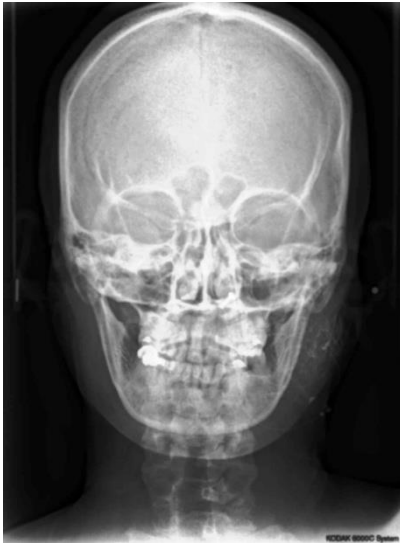

Fig. 4: PA-skull

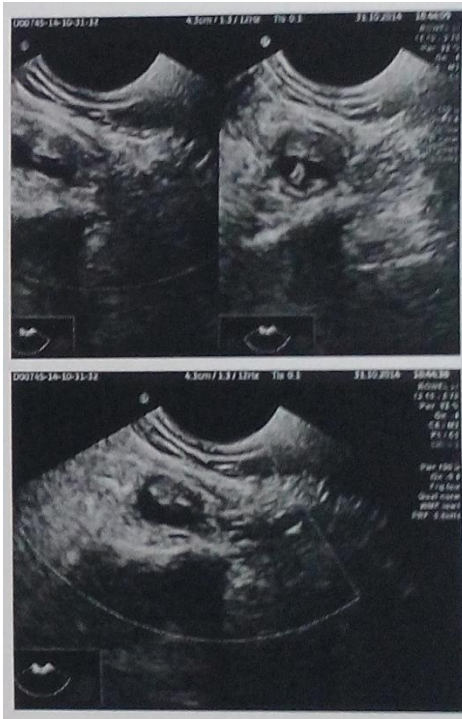


Fig. 5: Ultrasonography

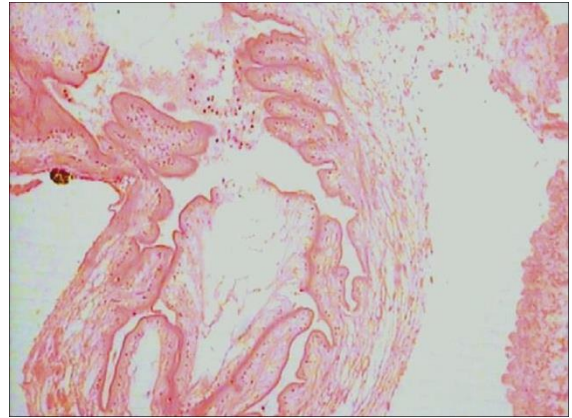


Fig. 6: Histopathological photomicrograph

These parasitic infections does not exhibits any pathognomonic clinical features and commonly presents as an asymptomatic swellings with no bleeding, pulsations, etc.^{5,11} Hence includes mucoceles, benign tumor of the minor salivary glands, lipoma, fibroma, hemangioma, myoma, glandular cell tumor,¹¹ sebaceous cyst,⁵ etc as differential diagnosis. A preoperative diagnostic investigation can be performed using fine-needle aspiration cytology^{12,13} followed by conventional radiography to rule out calcifications in muscle tissue.¹³ If necessary advanced imaging methods, such as computed tomography and magnetic resonance, may be done to assess neurological involvement¹⁴ and even has enzyme-linked immunosorbent assay (ELISA) or enzyme-linked immunoelectrotransfer blot test (EITB) as rare options as they are very expensive. However, surgical excision followed by histopathologic analysis is an often-employed means of diagnosis and treatment.¹³ In our case ultrasonography and color Doppler played a significant role in diagnosis as they revealed a cystic lesion in muscle bulk with hypo echoic pericystic area with mild perivascularity.^{15,16} However, surgical excision followed by histopathologic analysis is often employed as a definitive means of diagnosis and treatment.¹⁶

Thus there are several case reports in literature showing varying site predilection such as subcutaneous tissues, brain and skeletal muscles, etc. where the most commonly involved intraoral sites include tongue (42.15%), lips (26.15%) and buccal mucosa (18.9%). The most serious involvement is that of the central nervous system, followed by ocular involvement.¹⁷ Furthermore, it is interesting to note that involvement of masseter is extremely rare and such cases were reported by Reddi et al. (2001)¹⁸ and Mittal et al. (2008)¹⁹ both of which were diagnosed by USG and treated conservatively which are in consistent with similar case reports of Lavanya et al. (2015),²⁰ Ravi Kiran et al (2015),⁴ Alves et al. (2011),³ R. D. Jayasinghe et al (2015).¹ Thus our study is also in consistent with above studies in diagnosis and treatment.

Conclusion

Thus considering todays changing life styles and dietary habits of human beings, a thorough knowledge of

parasitic lesions is equally important as any other lesion and hence they should be included in differential diagnosis of soft tissue lesions occurring in head and neck. Apart from this, every effort should be made through health education to prevent and eradicate these group of lesions.

Conflict of Interest: None.

References

1. R.D. Jayasinghe, S.R. Gunawardane, M.A. M. Sitheeque and S. Wickramasinghe. A Case Report on Oral Subcutaneous Diofilariasis. Hindawi Publishing Corporation Case Reports in Infectious Diseases Volume 2015, Article ID 648278, 4 pages.
2. T. Jelinek, J. Schulte-Hillen, and T. L'oscher, Human dirofilariasis. *Int J Dermatol* 1996;35(12):872-5.
3. Alves A.P.N.N., Nogueira T.N.A.G., Teixeira M.J., Costa F.W.G, Sousa F.B. Tapeworm infection in the tongue. *Rev Inst Med Trop Sao Paulo* 2011;53(5):299-300.
4. Ravi Kiran Alaparthi, Samatha Yelamanchili, Purnachandrarao Naik Nunsavathu, Udaya Sode. Intraoral hydatid cyst: A rare case report. *J Indian Acad Oral Med Radiol* 2015;27(3).
5. Garcia HH, Del Brutto OH. Cysticercosis Working Group in Peru. Neurocysticercosis: updated concepts about an old disease. *Lancet Neurol* 2005;4:653-61.
6. Jay A, Dhanda J, Chiodini PL, Woodrow CJ, Farthing PM, Evans J, et al. Oral cysticercosis. *Br J Oral Maxillofac Surg* 2007;45:331-4.
7. T. Jelinek, J. Schulte-Hillen, and T. L'oscher. Human dirofilariasis. *Int J Dermatol* 1996;35(12):872-5.
8. Khanna S, Mishra SP, Gupta D, Kumar S, Khanna AK, Gupta SK. Unusual presentation of hydatid cyst: A case report. *Int J Res Appl Nat Soc Sci* 2013;1:25-8.
9. A.S. Dissanaikie, W. Abeyewickreme, M.D. Wijesundera, M.V. Weerasooriya, and M.M. Ismail. Human dirofilariasis I caused by *Dirofilaria (Nochtiella) repens* in Sri Lanka. *Parassitologia* 1997;39(4):375-82.
10. Soyulu L, Aydogan LB, Kiroglu M, Kiroglu F, Javadzadeh A, Tuncer I, et al. Hydatid cyst in the head and neck area. *Am J Otolaryngol* 1995;16:123-5.
11. Brasil. Ministério da Saúde, Secretaria de Vigilância em Saúde, Departamento de Vigilância Epidemiológica. Doenças infecciosas e parasitárias: guia de bolso. 8a ed. Brasília: Ministério da Saúde 2010. p. 357-60.
12. Mazhari NJ, Kumar N, Jain S. Cysticercosis of the oral mucosa: aspiration cytologic diagnosis. *J Oral Pathol Med* 2001;30:187-9.
13. Saran RK, Rattan V, Rajwanshi A, Nijkawan R, Gupta SK. Cysticercosis of the oral cavity: report of five cases and a review of literature. *Int J Paediatr Dent* 1998;8:273-8.
14. Jay A, Dhanda J, Chiodini PL, Woodrow CJ, Farthing PM, Evans J, et al. Oral cysticercosis. *Br J Oral Maxillofac Surg* 2007;45:331-4.
15. S. Pampiglione and F. Rivasi. Human dirofilariasis due to *Dirofilaria (Nochtiella) repens*: an update of world literature from 1995 to 2000. *Parassitologia* 2000;42(3-4):231-254.
16. L.L. Pereira, R.D. Coletta, L. C. Monteiro, V.Y .N. Ferreira, J. E. Leon, and P. R. F. Bonan. Dirofilariasis involving the oral cavity: report of the first case from South America. *Revistada Socie dade Brasileirade Medicina Trop* 2015;48(3):361-3.
17. Geramizadeh B. Unusual locations of the hydatid cyst: A review from Iran. *Iran J Med Sci* 2013; 38:2-14.
18. Chand S, Mishra M, Singh G, Singh A, Tandon S. Orofacial cysticercosis: Report of a rare case with review of literature. *Nat J Maxillofac Surg* 2016;7(2):209-12.
19. Debacq G, Moyano LM, Garcia HH. Systematic review and meta-analysis estimating association of cysticercosis and neurocysticercosis with epilepsy. *PLoS Negl Trop Dis* 2017;11(3):e0005153.
20. Lavanya RM, Kamath VV, Komali Y, Krishnamurthy S. Hydatid cyst of the buccal mucosa: An unusual presentation. *Indian J Dent* 2015;6(3):157-60. doi:10.4103/0975-962X.160350

How to cite this article: Soujanya SV, Harshavardhan, Kumar SM, Rao P. Parasitic cyst of cheek! A rare but considerable differential diagnosis: An ultrasonography and color doppler guided case report. *Int J Maxillofac Imaging* 2019;5(1):22-5.